

It's Not Pink Eye, Karen!
Welcome to Ocular Rosacea

Kaleb Abbott, OD, MS, FAAO
Assistant Professor
University of Colorado SOM
Dry Eye Clinic
Center for Ocular Inflammation



Sue Anschutz-Rodgers Eye Center
UNIVERSITY OF COLORADO
UNIVERSITY OF COLORADO MEDICAL CENTER uchealth

1

Financial Disclosures

- Investigator: Lexitas, Claris Bio, Trinity Life Sciences, Famy Life Sciences
- Consultant: Abbvie, Alcon, Bausch and Lomb, Barti, Dompe, Harrow, Optase, SunSnap Kids, Tarsus


**All relevant financial interests have been mitigated*

Sue Anschutz-Rodgers Eye Center
UNIVERSITY OF COLORADO
UNIVERSITY OF COLORADO MEDICAL CENTER uchealth

2

GEOFFREY CHAUCER
The Canterbury Tales

- 1387
- The Summoner
- Described his rosacea and facial redness
- Details treatments consisting of
 - Mercury
 - Lead
 - Brimstone
 - Borax
 - Cream of tartar
 - Arsenic ointment
- Blamed the rosacea on his drinking of strong red wine




3

An Old Man and his Grandson
Domenico Ghirlandaio

This grandfather has rosacea:

- Rhinophyma
- Telangiectatic blood vessels of the face
- Slight puffiness of the eyelids



4



5

Rosacea

Sue Anschutz-Rodgers Eye Center
UNIVERSITY OF COLORADO
UNIVERSITY OF COLORADO MEDICAL CENTER uchealth

6

What is rosacea NOT...

- Purely
 - Endocrine
 - Bacterial
 - Demodex
 - Environment
 - Genetics
 - Skin complexion

Sun Anschutz-Rodgers Eye Center
uchealth

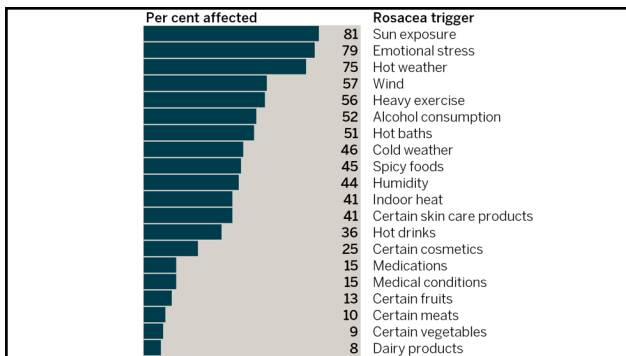
13

Best "treatment" is avoidance of triggers

- Spicy foods
- Foods high in histamines
 - Red wine
 - Aged cheese
 - Yogurt
 - Beer
 - Cured pork products
- Alcohol
- Climate
 - Sun
 - Extreme temperatures
 - Changing temperatures
 - Wind
- Strenuous exercise
- Stress, anxiety, poor sleep
- Fragrances
- Skincare products
- Topical steroids
- Chemicals
 - Witch hazel
 - Camphor
 - Menthol, eucalyptus oil, peppermint oil
- Isopropylalcohols
- Mechanical scrubs
- Men's skincare products are notoriously bad

Sun Anschutz-Rodgers Eye Center
uchealth

14



15

Sun Exposure

- Sunlight (UVB)
 - Stimulates angiogenesis
 - Stimulates dilation and spreading of roots
- Sunscreen options:
 - EltaMD UV Clear
 - Colorescience All Calm

Sun Anschutz-Rodgers Eye Center
uchealth

16

pH Balance

- Skin is naturally slightly acidic
 - pH = 5.4
- Soap is alkaline/basic
 - pH usually 8-9
- These patients respond well to simple, gentle cleansers
 - CeraVe Hydrating Facial Cleanser
 - Vanicream

Sun Anschutz-Rodgers Eye Center
uchealth

17

The Many Faces of Rosacea

Sun Anschutz-Rodgers Eye Center
uchealth

18

Four Types of Rosacea

- Erythematotelangiectatic
- Papulopustular
- Phymatous
- Ocular

*this categorization is being phased out




Sun Anschutz-Rodgers Eye Center
ucbahealth
Sharma, Aruj, et al. "Rosacea management: a comprehensive review." *Journal of cutaneous medicine and surgery* 21.5 (2015): 1585-1594.

19

Erythematotelangiectatic

- "Vascular rosacea"
- Prominent redness
- Persistent telangiectatic vessels
- Dilated blood vessels
- Central face
- Neural and vascular component
 - Both are hyperreactive



Sun Anschutz-Rodgers Eye Center
ucbahealth
Sharma, Aruj, et al. "Rosacea management: a comprehensive review." *Journal of cutaneous medicine and surgery* 21.5 (2015): 1585-1594.

20

Erythematotelangiectatic

- Starts with transient blushing in response to triggers
 - Embarrassment
 - Spicy foods
 - Alcohol
- Dilated blood vessels slowly develop over years



Sun Anschutz-Rodgers Eye Center
ucbahealth
Sharma, Aruj, et al. "Rosacea management: a comprehensive review." *Journal of cutaneous medicine and surgery* 21.5 (2015): 1585-1594.

21

Papulopustular Rosacea ("Acne Rosacea")

- Due to inflammation and demodex (80%)
- Typical acne treatments and vitamin A derivatives may worsen this
- Affects central face more
- Can cause thickening of skin
- Presents later than typical acne
 - Post-adolescents
 - Middle of adulthood
- Responds well to sulfur, azelaic acid, demodex treatments (lotilaner)

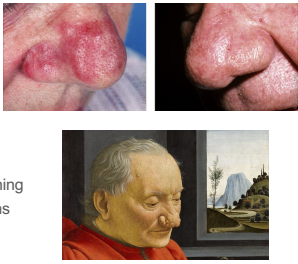


Sun Anschutz-Rodgers Eye Center
ucbahealth
Sharma, Aruj, et al. "Rosacea management: a comprehensive review." *Journal of cutaneous medicine and surgery* 21.5 (2015): 1585-1594.

22

Phymatous Rosacea

- "Oil gland rosacea"
- Skin thickening
- Larger nose appearance
- Disfiguring appearance
- Greasy appearance
- Oil glands continuously enlarge
- Late-stage tissue fibrosis and thickening
- Does not respond well to OTC options



Sun Anschutz-Rodgers Eye Center
ucbahealth
Sharma, Aruj, et al. "Rosacea management: a comprehensive review." *Journal of cutaneous medicine and surgery* 21.5 (2015): 1585-1594.

23

"The perfect cure of acne rosacea is, in fact, never accomplished."

- Dr. Thomas Bateman (1812)


Sun Anschutz-Rodgers Eye Center
ucbahealth
Sharma, Aruj, et al. "Rosacea management: a comprehensive review." *Journal of cutaneous medicine and surgery* 21.5 (2015): 1585-1594.

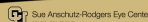

24

OTC Treatments

Sulfur

- PROcure Rosacare
 - Liquorish
 - Niacinamide
 - Chromium oxide greens
 - *Cancels out reds*
- Cetaphil Redness Relief
 - Liquorish
 - Niacinamide
 - Caffeine
- Prosacea Rosacea Gel
 - Contains sulfur
- Sulfur bar soaps
- Azelaic acid
 - The Ordinary
 - Paula's choice
 - Naturium)
- CeraVe Hydrating Facial Cleanser
- Vanicream




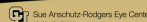

 Sue Anschutz-Rodgers Eye Center
 School of Medicine
 UNIVERSITY OF CALIFORNIA, SAN DIEGO MEDICAL CENTER
 ucbahealth

25

Prescription Rosacea Treatments



- Topical
 - Metronidazole
 - Azelaic acid
 - Ivermectin
 - Niacinamide
 - Retin-A
 - Pimecrolimus/tacrolimus
 - Steroids
 - Antibiotics (clindamycin, erythromycin, azithromycin)
 - Brimonidine cream
- Sodium sulfacetamide wash
- Benzoyl peroxide
- Oral
 - Antibiotics
 - Tetracyclines (minocycline, doxycycline, tetracycline)
 - Metronidazole, azithromycin, clarithromycin, erythromycin
 - Burst and taper
 - Long-term
 - Omega-3 supplementation
 - Isotretinoin
- Surgical/laser/light treatments



 Sue Anschutz-Rodgers Eye Center
 School of Medicine
 UNIVERSITY OF CALIFORNIA, SAN DIEGO MEDICAL CENTER
 ucbahealth

26

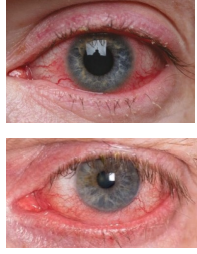
Ocular Rosacea



 Sue Anschutz-Rodgers Eye Center
 School of Medicine
 UNIVERSITY OF CALIFORNIA, SAN DIEGO MEDICAL CENTER
 ucbahealth

27

Background / Confusion

- Dermatology
 - About 20% of rosacea patients present initially with ocular rosacea
 - Facial rosacea typically precedes ocular rosacea
- Eyecare
 - Found in 58-75% of rosacea patients
 - Up to 90% of ocular rosacea patients have minimal skin findings




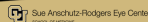

 Sue Anschutz-Rodgers Eye Center
 School of Medicine
 UNIVERSITY OF CALIFORNIA, SAN DIEGO MEDICAL CENTER
 ucbahealth
Shimizu A, et al. Ocular Rosacea. *Survey of Ophthalmology*. 2016;61(5):345-354. doi:10.1016/j.survophthal.2016.05.002

28

Signs

- Lid margin telangiectasia
- Lid erythema
- Blepharitis
- Meibomian gland dysfunction
 - Reduced MGLS
 - Thickened meibum
 - Rapid TBUT
- Conjunctival injection
- Saponification



 Sue Anschutz-Rodgers Eye Center
 School of Medicine
 UNIVERSITY OF CALIFORNIA, SAN DIEGO MEDICAL CENTER
 ucbahealth
Shimizu A, et al. Ocular Rosacea. *Survey of Ophthalmology*. 2016;61(5):345-354. doi:10.1016/j.survophthal.2016.05.002

29

Symptoms – “the great masquerader”

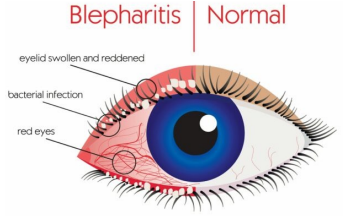
- Irritation
- Foreign body sensation
- Grittiness
- Burning
- Redness of eyes/eyelids
- Tearing
- Pain
- Fluctuating vision
- Photophobia
- Chalazia/hordeola and styes

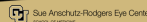

Blepharitis | Normal

eyelid swollen and reddened

bacterial infection

red eyes



 Sue Anschutz-Rodgers Eye Center
 School of Medicine
 UNIVERSITY OF CALIFORNIA, SAN DIEGO MEDICAL CENTER
 ucbahealth
Vinik, Alan G. et al. "Ocular rosacea: common and confusing." *Journal of the American Academy of Ophthalmology* 194 (2015): 208-241.

30

Abnormal Innate Immune Response

- Exaggerated response of our innate immune system to the environment
 - Increased toll-like receptor 2 (TLR2) expression epidermal keratinocytes
 - Stimulation of TLR2 receptors (by environmental triggers) leads to increased KLK5 (serine protease) which produces cathelicidin

Sun, J. Young, et al. "Increased expression of cathelicidin by direct activation of cutaneous epithelial keratinocytes is strongly correlated to the upregulation of TLR2." *Investment Ophthalmol Vis Sci* 45(10):2014-2018, 2004.

31

Cathelicidin

- Cathelicidins are antimicrobial peptides capable of inducing inflammation and angiogenesis via innate immunity
- Normal = Cathelicidin is produced in response to pathogens
- Abnormal = Cathelicidin is produced in response to normal environmental stimuli / triggers

Sun, J. Young, et al. "Increased expression of cathelicidin by direct activation of cutaneous epithelial keratinocytes is strongly correlated to the upregulation of TLR2." *Investment Ophthalmol Vis Sci* 45(10):2014-2018, 2004.

32

Vascular Endothelial Growth Factor

- Cathelicidin → increases VEGF release
- Produces telangiectasias/dilation
- Abnormal vessels are pro-inflammatory
- Increased interleukins and MMPs
- Cosmetic redness
- Meibomian glands compression
- Meibomitis
- Warmth

Sun, J. Young, et al. "Increased expression of cathelicidin by direct activation of cutaneous epithelial keratinocytes is strongly correlated to the upregulation of TLR2." *Investment Ophthalmol Vis Sci* 45(10):2014-2018, 2004.

33

OSD Manifestations

- Meibomian gland dysfunction (hyper or hypo)
 - Lid margin notching
 - Scarring
 - Lid margin thickening
- Tear film stability
- Ocular surface inflammation
- Altered microbiome (including demodex)
- Hordeola, chalazia, styes
- Conjunctivitis, keratitis
- Dermal edema

Tawamleh, Shadiyah, Nathan Wong, and Elin Chen. "Ocular manifestations of rosacea & clinical review." *Ocular Allergy Immunology* 4:10 (2019): 100-110.

34

How bad can it get?

- Corneal neovascularization
- Corneal scarring
- Phlyctenules
- Limbal stem cell deficiency
- Neurotrophic keratitis
- Cicatrizing conjunctivitis
- Entropion/ectropion
- Corneal ulceration or perforation

Sun, J. Young, et al. "Increased expression of cathelicidin by direct activation of cutaneous epithelial keratinocytes is strongly correlated to the upregulation of TLR2." *Investment Ophthalmol Vis Sci* 45(10):2014-2018, 2004.

35

Sun, J. Young, et al. "Increased expression of cathelicidin by direct activation of cutaneous epithelial keratinocytes is strongly correlated to the upregulation of TLR2." *Investment Ophthalmol Vis Sci* 45(10):2014-2018, 2004.

36

Demodicosis of the face

- Pilosebaceous glands
- Commonly seen with facial rosacea
- Causes localized folliculitis and inflammation
- Doesn't respond to typical rosacea treatments




Sue Anschutz-Rodgers Eye Center
School of Medicine
UNIVERSITY OF CALIFORNIA, SAN DIEGO, MEDICAL CAMPUS | uchealth | Fisher, P. M. N. "Rosacea, an infectious disease: why rosacea with impatiens should be considered a demodicosis." Journal of the European Academy of Dermatology and Venereology 30.7 (2012): 1037-1032.

37

Demodex blepharitis

- Commonly seen with rosacea
- Arachnid parasite
- Species
 - Demodex folliculorum
 - Demodex brevis
- Light averse
- Life cycle is ~3 weeks
- Females lay 15-20 eggs (once)
- Crawl 1cm per night

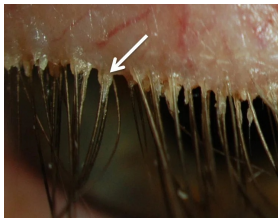



Sue Anschutz-Rodgers Eye Center
School of Medicine
UNIVERSITY OF CALIFORNIA, SAN DIEGO, MEDICAL CAMPUS | uchealth

38

Collarettes

- Base of the eyelashes
- Composed of waste products, keratin, lipids, epithelial cells

Sue Anschutz-Rodgers Eye Center
School of Medicine
UNIVERSITY OF CALIFORNIA, SAN DIEGO, MEDICAL CAMPUS | uchealth

39



Ocular Rosacea Treatments

Sue Anschutz-Rodgers Eye Center
School of Medicine
UNIVERSITY OF CALIFORNIA, SAN DIEGO, MEDICAL CAMPUS | uchealth

40

Inflammatory Treatments

- Topical immunomodulators
 - Cyclosporine
 - Lifitegrast
- Antibiotic/steroid drops
- Corticosteroid drops
- Oral antibiotics (azithromycin, doxycycline)
- Topical azithromycin
- IPL
- ? OTC brimonidine







Sue Anschutz-Rodgers Eye Center
School of Medicine
UNIVERSITY OF CALIFORNIA, SAN DIEGO, MEDICAL CAMPUS | uchealth

41

MGD/Blepharitis/Hordeola Treatments

- Lid hygiene (ex tea tree oil)
- Oral omega-3s
- ? Warm compresses
- Topical azithromycin
- Oral doxycycline
- Procedures
 - Blepharoxfoliation
 - Thermal pulsation
 - IPL
 - MG probing
- Lotilaner (demodex blepharitis)
- Lotilaner (? MGD)

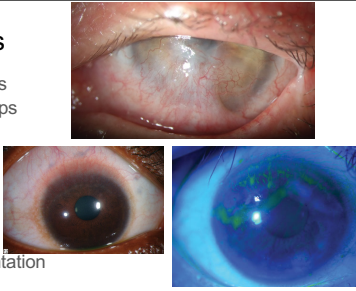




Sue Anschutz-Rodgers Eye Center
School of Medicine
UNIVERSITY OF CALIFORNIA, SAN DIEGO, MEDICAL CAMPUS | uchealth

42

Keratitis Treatments

- Topical immunomodulators
- Autologous serum eyedrops
- Topical corticosteroids
- ? Punctal plugs
- Oral doxycycline
- Scleral lenses
- Penetrating keratoplasty
- Limbal stem cell transplantation

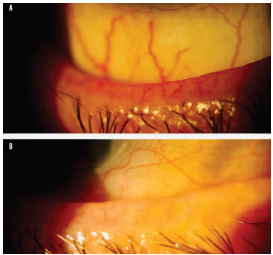


Sue Anschutz-Rodgers Eye Center
ucbealth

43

IPL for Ocular Rosacea

- Highly effective
- Treating abnormal vasculature
- "Sealing off" telangiectatic vessels
- Improves
 - Inflammation
 - MGD
 - Lid margin telangiectasias
 - Demodex
 - Bacterial overload
 - Blink mechanics
 - Cosmetic appearance




Sue Anschutz-Rodgers Eye Center
ucbealth

44

Future and Off-label Treatments

- RASP inhibitors
- Lotilaner ointment for the eyelids
- Brimonidine drops
- Vasoconstrictors for the eyelids
- Compounded facial treatments
 - Ivermectin/metronidazole/azelaic acid




Sue Anschutz-Rodgers Eye Center
ucbealth

45

Lifestyle Changes

- Healthy fats high in omega-3s
- Anti-inflammatory foods
 - Berries, nuts, turmeric,
- Prebiotics
 - Foods high in fiber
 - Onions, greens, garlic, asparagus, oats, flaxseeds
- Probiotics
 - Fermented foods (ex. yogurt, kimchi, saurkraut, kefir, kombucha)
- Limit alcohol consumption
- Sun protection
- Prioritize sleep



Sue Anschutz-Rodgers Eye Center
ucbealth

46

Summary

- Ocular rosacea is commonly missed
- Prevalent in cases of facial rosacea
- Can occur with or without rosacea
- Symptoms can be non-specific
- Manifestations are wide-spread
- Despite no single FDA approved treatment, we have options to help these patients



Sue Anschutz-Rodgers Eye Center
ucbealth

47

The Many Faces of Rosacea



Bill Clinton
WC Fields
JP Morgan
Prince Williams
Megan Rapinoe
Rosie O'Donnell
Princess Diana
Cameron Diaz

48

