

Optometric Laser Procedures: Pearls, Pitfalls, and How to Successfully Incorporate Into Your Practice

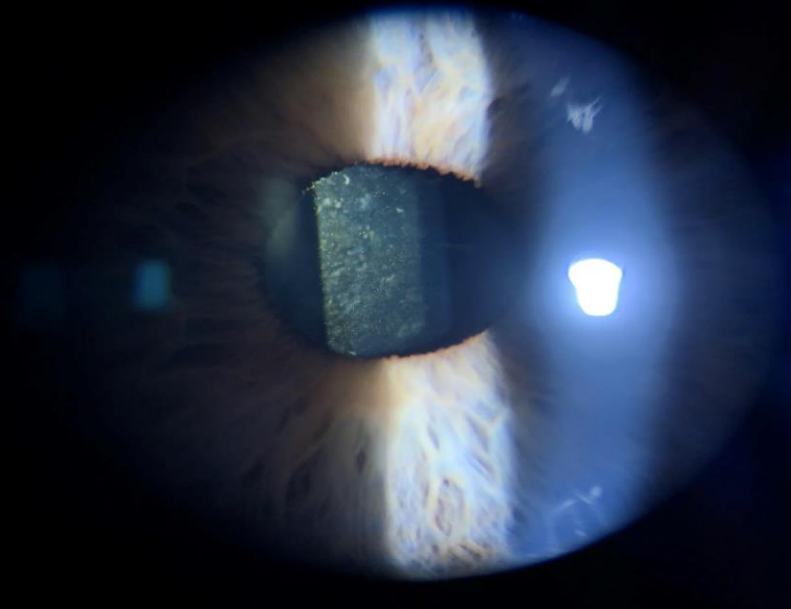
Joe Munsell O.D., Dipl. ABO
Cheyenne Vision Clinic, Laramie Vision Clinic
jmunsell25@gmail.com

Financial Disclosure: No relevant relationships.

Optometric Laser Procedures

- 14 Current state with laser privileges
- 5 more currently pushing legislation

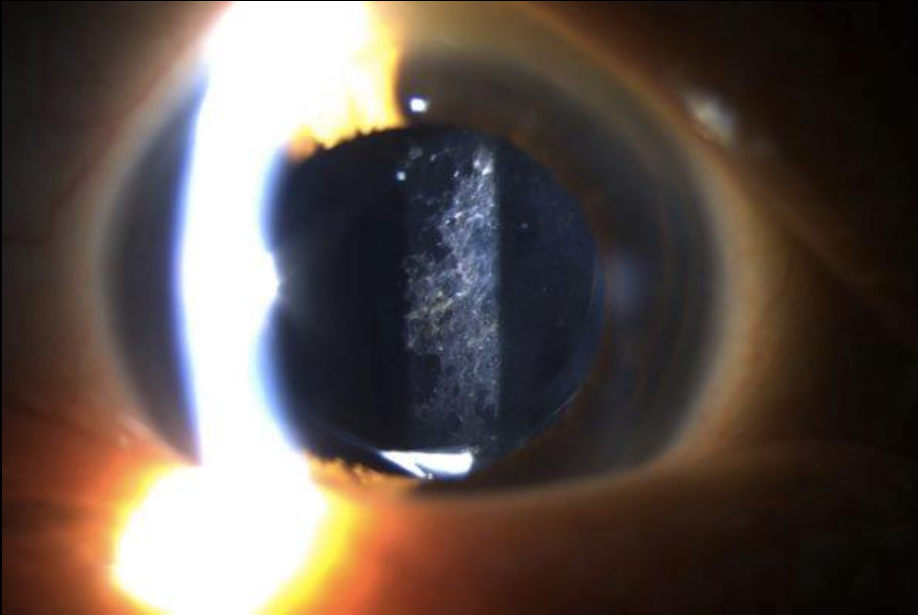
PCO & YAG Capsulotomy



Posterior Capsular Opacity: Clinical Features

- 20-40% incidence, months to year following CE
 - Young>old
 - Complicated>age related
 - Silicone>Acrylic
 - IOL Design
 - Accommodating IOL
- Mechanism: Cataract surgery induces a wound-healing response in the lens, and leftover LECs proliferate and migrate across the posterior capsule and undergo lens fiber regeneration and EMT

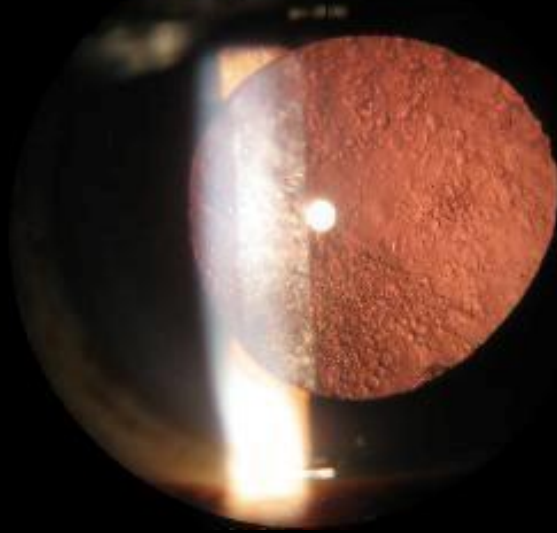
Types- Fibrotic



- Proliferation and migration of LEC's that undergo EMT into myofibroblasts
- Produce folds and wrinkles in posterior capsule
- Typically occurs 2-6 months post CE

Types: Pearl

©NJOPH.com



- LEC's located at lens equatorial region
- Causes attempted regeneration of crystallin lenticular fibers forming Elschnig pearls and a Soemmering ring
- Typically occurs 3-5 years post CE

Types: Mixed



Posterior Capsular Opacities- What's Surgical?

- Reduced VA, visually significant defined as >2 line reduction in snellen acuity or
 - Impaired contrast sensitivity
 - **Glare disability**
- Monocular diplopia
- Grading

Posterior Capsular Opacity: Management

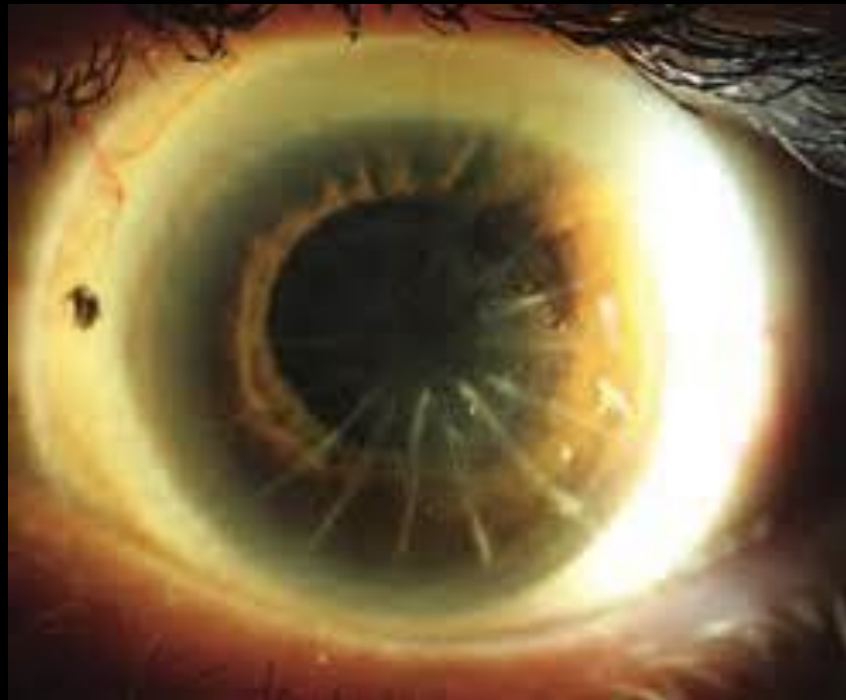YAG Capsulotomy

- Photo Disruptive- energy levels cause tissue to reduce to plasma effectively disintegrating the tissue
- Pigment independent
- 1064 nm and pulse length of 4ns

YAG Capsulotomy: Careful Patient Selection

- When first starting out
 - Uncomplicated
 - No confounding factors
 - Long-standing patient
 - Personality
 - Careful with high myopes
 - Studies show 0.6- 2.5% retinal detachment incidence
 - Filtering Blebs?

YAG Capsulotomy



YAG Capsulotomy: Pearls

- Wait **3 months** post CE
 - Lens Exchange?
 - Dysphotopsias
- High quality consent form
- Expectations
- Procedure not Surgery

- Pre-op: VA's, IOP, BP, consent, **Optomap**
 - Anesthetic, tropicamide, brimonidine
 - **Checklist**



Cheyenne Vision Clinic

1854 Dell Range Blvd. Cheyenne, WY
307-634-3937

YAG Posterior Capsulotomy Informed Consent

Your provider has informed you about your condition and recommends a surgical or medical procedure(s) be performed. This consent form is to show written confirmation these discussions occurred. This is intended to make you (the patient) better informed so you may give or withhold your consent to the proposed procedure(s).

Condition: Dr. _____ has explained that the following condition exists:

Posterior Capsular Opacity: following cataract surgery (the removal of the natural cloudy lens and replacing it with a new synthetic lens) a membrane may thicken over time, developing a cloudiness behind the artificial lens leading to visual blurring, glare, and tension on the lens.

Proposed Procedure(s): YAG Capsulotomy Right Eye / Left Eye

This in-office procedure uses a laser to open the membrane and release tension on the lens capsule by using a beam of light. Your eyes will be dilated. Sometimes a contact lens may be used to help focus the laser; if needed, anesthetic eye drops will be administered. This medication may cause transient blurred vision following the procedure. The procedure itself takes less than 5 minutes and requires multiple pulses of light to achieve the desired effects. Although the procedure is typically painless, you may feel slight pressure from the contact lens. You will see a red focusing light and a white light from the microscope. A small snap or "pop" may be heard during the procedure. Visual improvement may take several days and seeing some "floaters" is common.

Complications and Risks:

I am aware that in addition to the benefits of the recommended procedure, there are also risks involved with any operation. Eye pressure may become elevated following the procedure and will be treated accordingly. While complications are rare, due to the laser applying energy behind the lens, a retinal tear, swelling, or detachment may occur. Although these retinal problems arise naturally in the eye, increased energy in the eye slightly elevates the risk that these may appear. By signing this consent form it is understood the possible complications related to the procedure are the most common but not all inclusive. Others include but are not limited to: adverse side effects to drugs, allergic reactions, bleeding, blood clots, infections, and loss of vision.

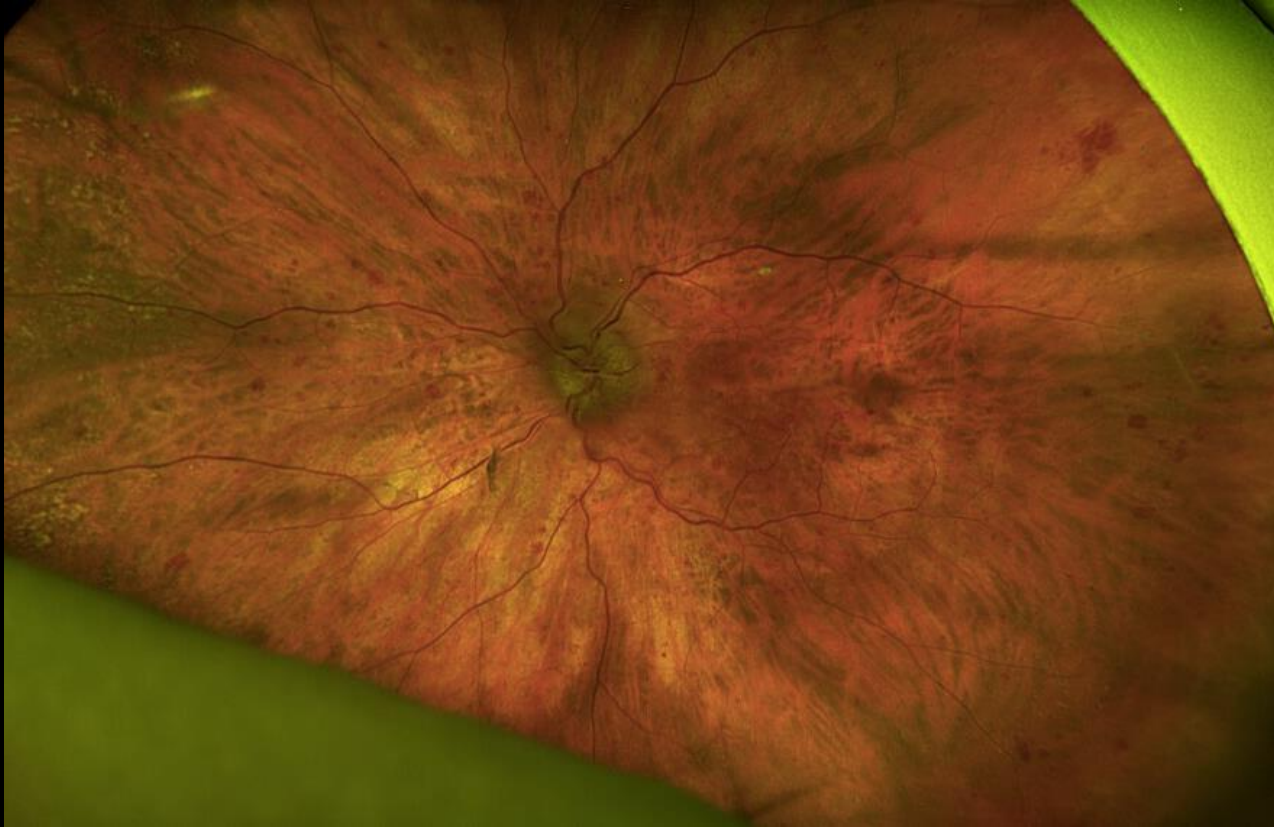
Proposed Benefits: reduction in halos/streaks/glare and improved vision.

Alternative Treatments: Monitoring condition

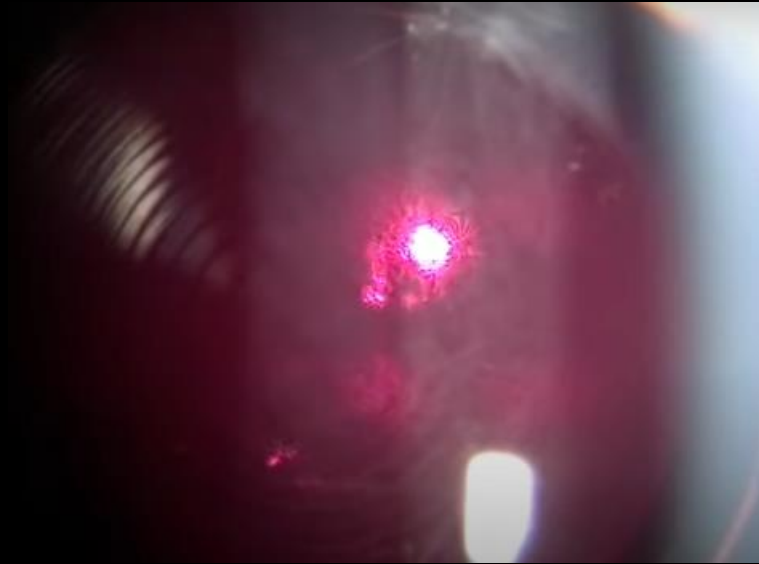
I understand the potential risks, complications, and side effects associated with any surgery. Although most procedures have good results, I understand that no guarantee has been made to me about the results of this procedure. The alternative treatments and their risks and benefits have been explained to my satisfaction. I have had the opportunity to ask any questions regarding the procedure and they were answered adequately. I agree to follow all instructions, follow up as directed and notify my doctor if any problems arise. I hereby give my consent for the procedure of posterior capsulotomy using the YAG laser.

Patient's printed name: _____
Patient signature: _____
Date: _____
Doctor signature: _____

YAG Cap Case: PT R on pre-op optomap

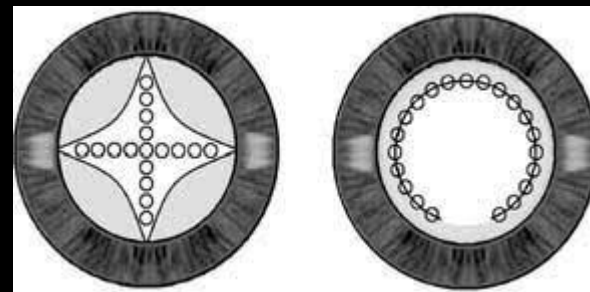


YAG Capsulotomy- courtesy Dr Mahootchi



YAG Capsulotomy- Pearls

- Lens
 - Abraham capsulotomy lens?
 - Gel artificial tear
 - No Lens
- Procedure
 - Settings
 - Energy 1.3mJ -2.5 mJ (higher starting energy on fibrous PCO) personally: **1.7mJ**
 - Offset: 125-500 microns, personally: **250 microns**
 - Multiple patterns/techniques
 - Cruciate: most common- **start perpendicular**



YAG Capsulotomy

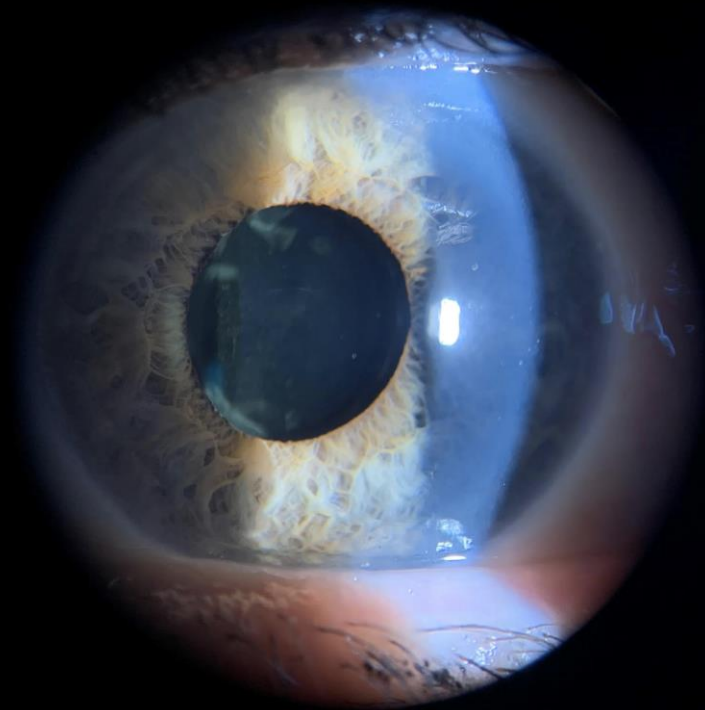
- Less total energy = less risk of complications: **Higher energy + less applications**
- Post Op
 - If lens used, irrigate eye following removal
 - 1 drop alphagan
 - IOP in 20 minutes
 - Drops?
 - Follow up in 1 week
 - 90 day global period

Plan: Perform ____ YAG CAPSULOTOMY ____ OS ____ for ____ POSTERIOR CAPSULE OPACITY _____. History taken, medication and medication allergies reviewed. Blood Pressure_126__/_79_, Pulse__68__. Discussed the possibility of the need for further procedure or therapy.

Procedure: Educated on ____ YAG CAP _____. Patient understood procedure and risks. Consent given by patient. Instill one drop __tetracaine_____, Ou_____, instill one drop __brimonidine and tropicamide_____, Os_____. 10 minutes after drops a YAG capsulotomy was performed. Number of shots__18____, energy/shot __1.7mj____ and total energy __30.6mj_____. Patient tolerated procedure. Patient left stable. Post-op medications __Pred forte OS BID_____, _____. Followup 1 hour and ____1 week____. Patient informed to return to clinic if they experience retinal detachment symptoms, redness, blur or pain.

YAG Capsulotomy

- Complications
 - IOP spike- transient
 - Inflammation
 - IOL pitting: 33%
 - Floaters
 - CME
 - Retinal detachment (rare except in high myopes) .5%



YAG Capsulotomy- Pitfalls

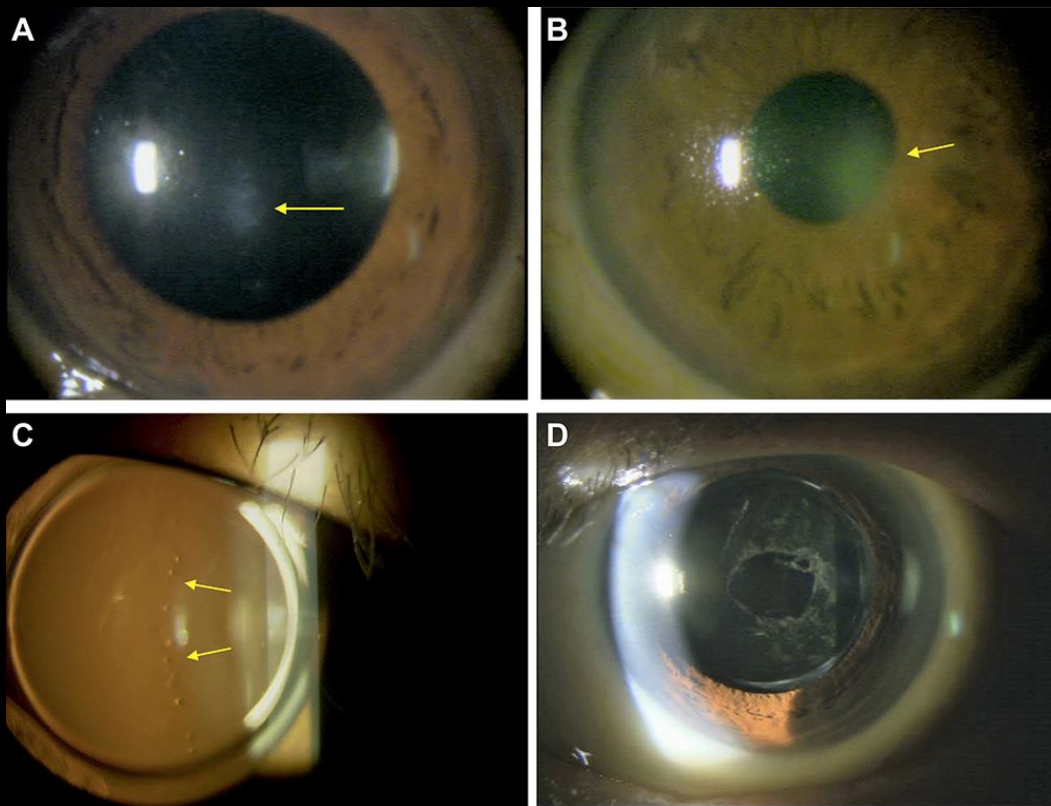
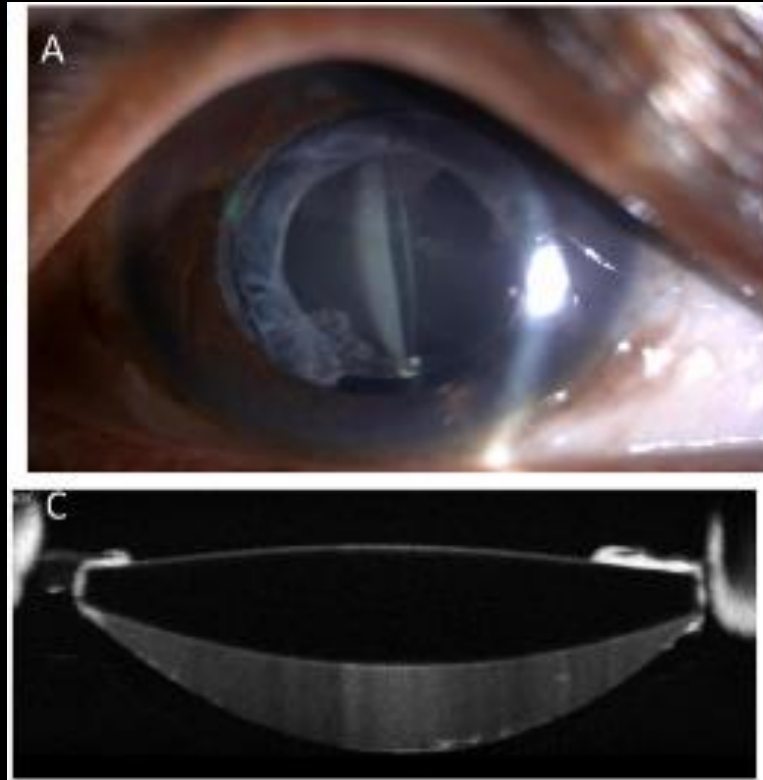
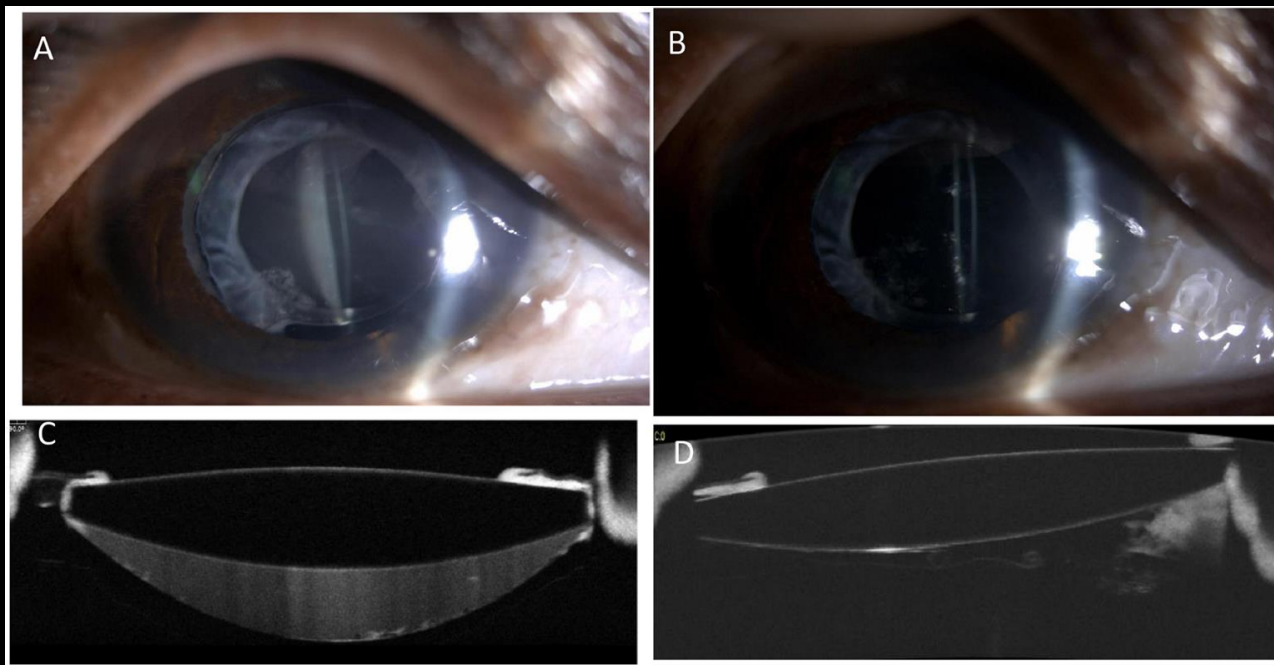


Image via
NIH

YAG Capsulotomy



YAG Cap Cases



Capsular Bag Distension Syndrome

- <1% of cases
- Early (non cellular/ inflammatory) vs Late (fibrotic)
- More likely in high axial lengths
- Contact between anterior capsule and IOL leads to fluid accumulation
- Turbid fluid reduces VA and leads to a myopic shift
- Treatment
 - YAG, aspiration, vitrectomy
- Careful!!!!!! **Propionibacterium acnes** infection may be present within bag

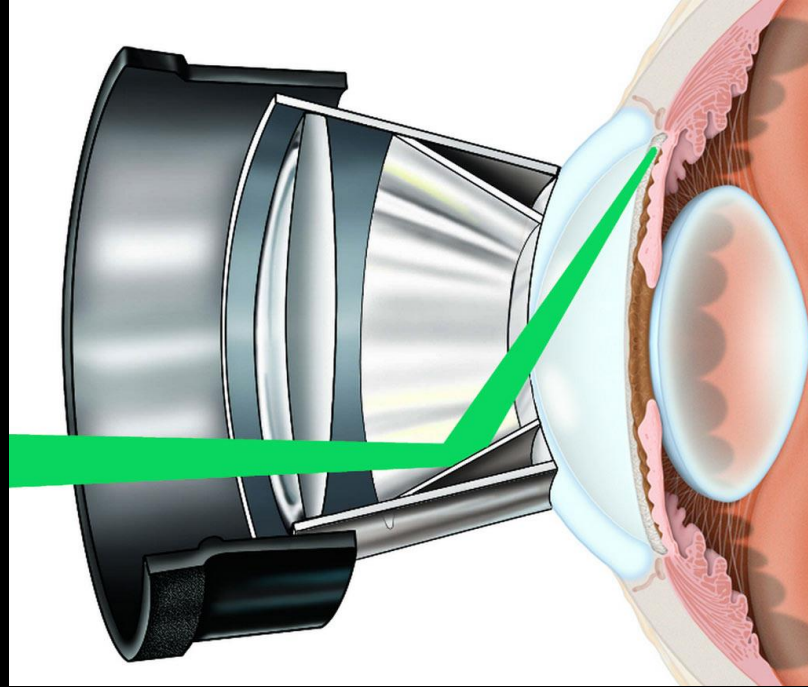
YAG Capsulotomy: Successful Practice Integration

- Overly Prepare
- Scheduling
 - Half day of procedures vs work into normal schedule
- Tech workup
- Marketing
 - Internal, referrals, word of mouth
 - Educate Staff
- Seek advice

SLT

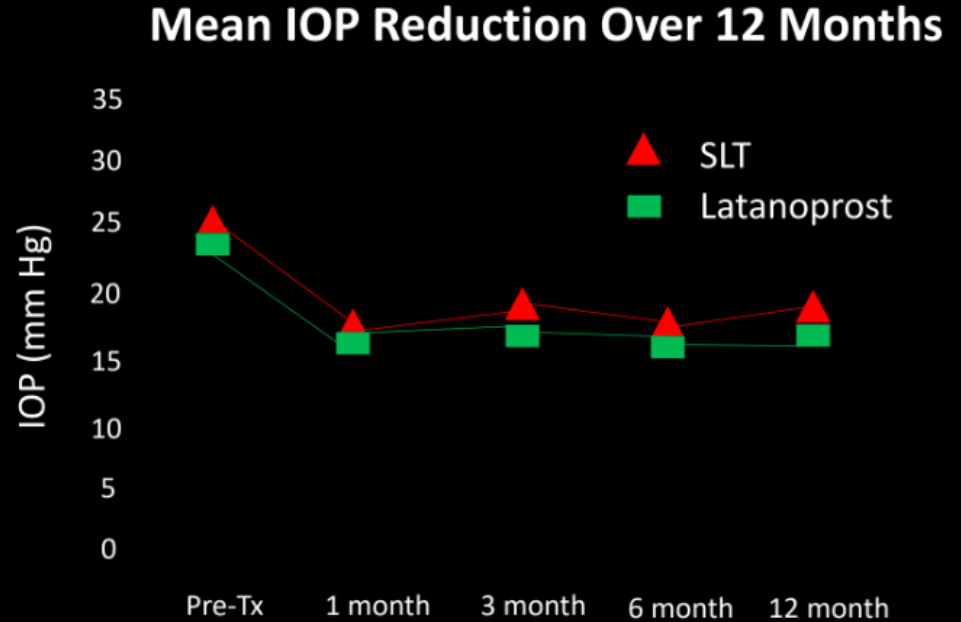
- Outpatient procedure
- Painless
- Q-switch frequency doubled 532 nm:YAG laser
- Mechanism of Action:
 - Selective **targeting of pigmented TM cells** to prevent structural or coagulative damage
 - Causes chemical mediators to attract macrophages and phagocytes to cause structural remodeling

Selective Laser Trabeculoplasty



Data Review: McIlrath (2006)

- Newly diagnosed OAG
- Received either SLT or latanoprost
- Results: 30% reduction in both groups



B. Lonsberry

Data Review: LiGHT Study- 3 yr data

- Outcomes: health related quality of life, cost effectiveness, efficacy
- Randomized to Laser (initial SLT followed by routine medical therapy)
vs medicine (initialed followed by routine medical therapy)
- 360 degree treatment- no steroid/NSAID post op

Data Review: LiGHT Study- 3 year data

- Results:
 - QoL: no difference
 - Target IOP
 - SLT: 95%
 - Meds: 93.1%
 - **78%** of SLT patients at target were on 0 medications
 - SLT gave medication free IOP control in 74.2% of patients
 - Rates of deterioration
 - SLT: 3.8%
 - Meds: 5.8%
 - Glaucoma Surgeries
 - SLT: **0**
 - Meds: **11**

Data Review: LiGHT Study- New 6 year data

- 82.8% of study participants extended
- Results:
 - QoL: no difference
 - 69.8% of SLT patients remained at target with 0 medications
 - Rates of disease progression
 - SLT: 19.6 %
 - Meds: 26.8%
 - Glaucoma Surgeries
 - SLT: 13
 - Meds: 32

Data Review Conclusions

- Evidence shows that SLT is the most cost effective first line treatment for OAG and OHT while providing better clinical outcomes

Lower Energy Higher Frequency?

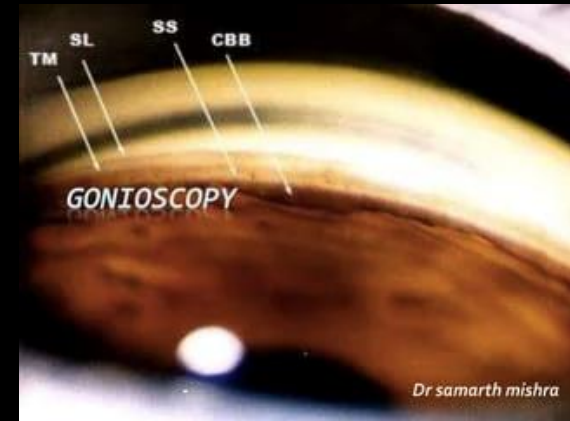- Study presented at ARVO from Italy:
 - Low energy (0.4 mJ, 50-60 spots) to be repeated every year vs standard SLT protocol (0.8mJ to 1.0mJ, 80 to 120 laser pulses) repeated as needed vs traditional ALT.
 - Results
 - 10-year medication-free rates to be:²⁰
 - ALT: 22.6%
 - Standard SLT: 25.0%
 - Low-energy annual SLT: 58.3%
 - They also found 10-year median times to medication treatment to be:²⁰
 - ALT: 2.8 years
 - Standard SLT: 3.2 years
 - Low-energy annual SLT: 6.2 years

Lower Energy Higher Frequency?

- Ongoing Coast Study
- We may have a shift in treatment protocol going forward
- Direct SLT

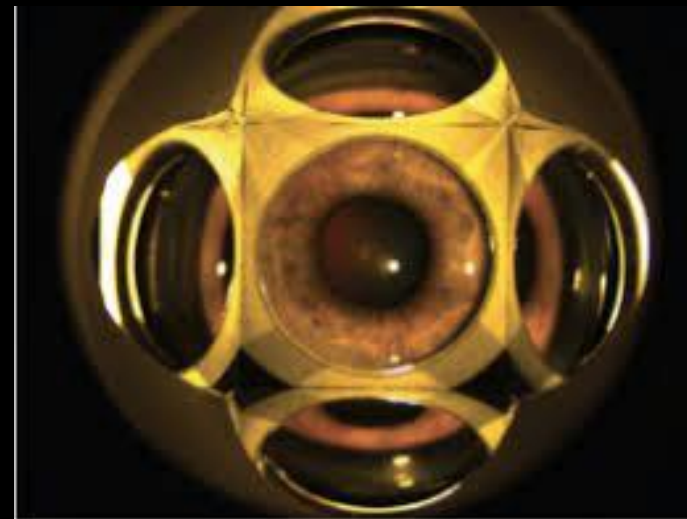
SLT Pearls

- We know it should be 1st line, why lag of acceptance?
 - Knowledge
 - Procedure NOT Surgery
 - Patient selection when starting
 - Familiarity with gonioscopy
 - Tips:
 - 4 mirror mini
 - Correct Coupling Agent
 - Removal of bubbles
 - Should be performed on all glaucoma patients



SLT- Procedure

- Pre OP
 - Informed consent, BP, pulse, meds, history of fainting, Optomap
 - alphagan
 - Pilocarpine?
 - Anesthetic OU
- Op
 - Laser settings
 - Energy: 0.6mJ- 1.2mJ (personally start at 1.0mJ)
 - Size: 400microns,
 - Duration: 3 ns, 1 pulse



TelScreen

NSU Oklahoma College of Optometry

SLT- Procedure

- Cavitation bubble formation 20 % of time
- 85 +/- 5 per 360
- Inferior angle has more pigment so titrate accordingly
- Post op
 - Instill drop of alphagan
 - Post op meds? SALT Study

Steroid after Laser Trabeculoplasty (SALT) Study

- 23.3mmhg IOP Preop for both groups
- At 12 week follow up:
 - Steroid group: 5.2 +/- 2.7mmhg
 - NSAID group: 6.2 +/-3.1 mmhg
 - Control: 3.0 +/- 4.3 mmhg

SLT

Follow up at 30 minutes, 1 week, 6-8 weeks

10 day global period

Stop current drop regimen?

Retreat?

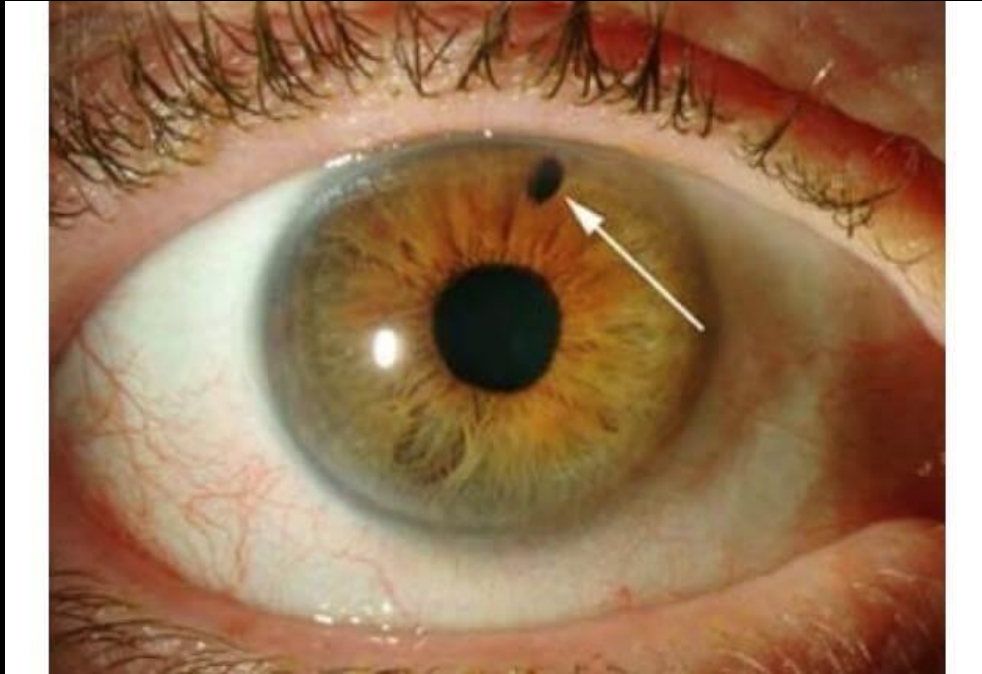
2014 Study (Khoury et.al)

POAG vs OHT

SLT Successful Integration

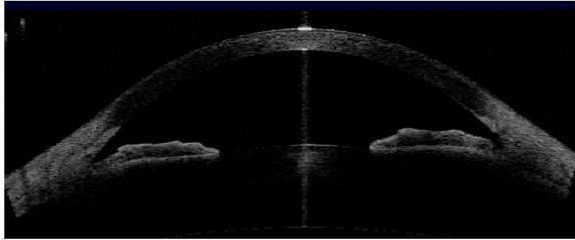
- Discuss with every glaucoma patient
- Overly Prepare- checklist
- Scheduling
 - Half day of procedures vs work into normal schedule
- Tech workup
- Marketing
 - Internal, referrals, word of mouth
- Seek advice
- Educate Staff

Laser Peripheral Iridoplasty

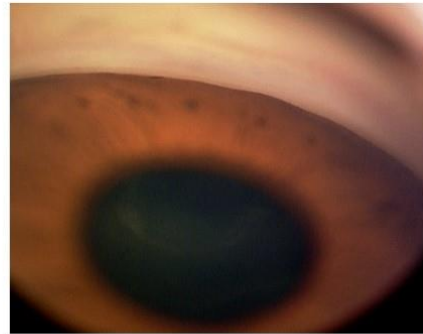
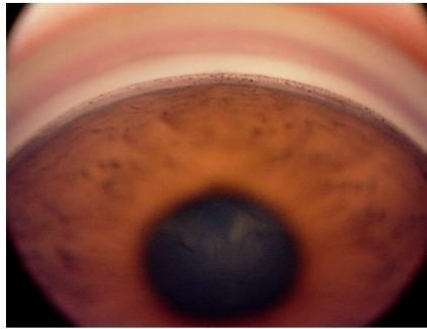
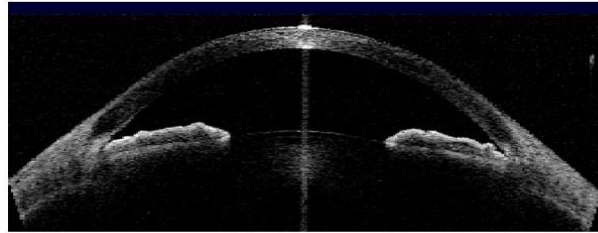


Angle Closure and Laser Peripheral Iridotomy

OPEN Angle



CLOSED Angle



AAC Management

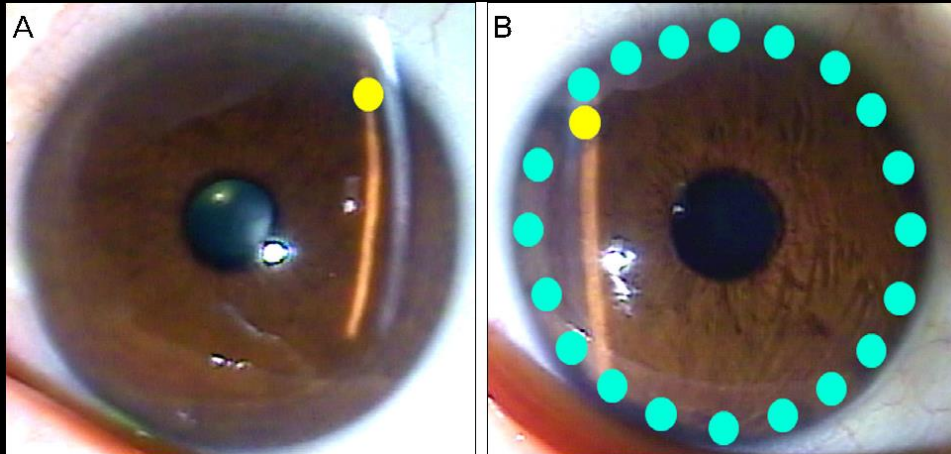
- Gonioscopy- indentation
- Topical and systemic lowering medications
- Oral acetazolamide 2 x 250 mg- non sequels
- Topical bet blockers or alpha 2 agonist (prostaglandins?)
- Topical steroid- alleviate pain and reduce inflammation
- Pilocarpine??- paradoxically shallow anterior chamber – avoid
- Have patient lay on back
 - Gravity induced posterior shift of lens iris diaphragm
- If no improvement start oral hyperosmotic- glycerine 1-2 g/kg/dose orally

AAC Management

ALPI -Argon Laser Peripheral Iridoplasty

An argon laser is used to treat the peripheral iris 360 degrees to cause photocoagulation burns to contract tissue away from the trabecular meshwork.

Higher long term failure rate and lower iop reduction when compared to conventional PGA therapy. Useful in cases where LPI cannot be performed (2016)



AAC Management

Clear Lens Extraction

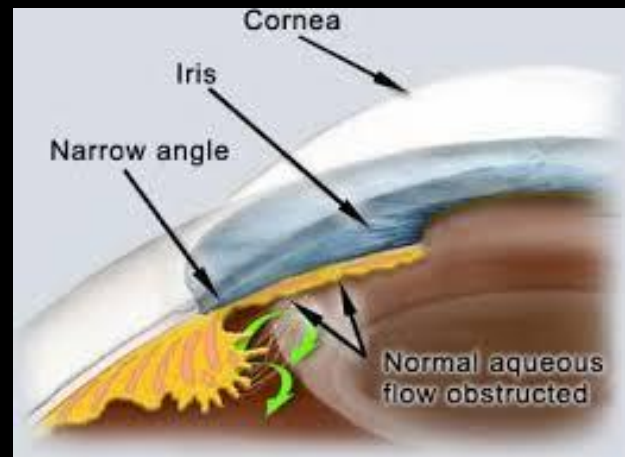
EAGLE Study (2016)-

155 patients with PAC and 263 with PACG, Of the 419 patients included, 208 underwent clear lens extraction and 211 standard care with laser iridotomy.

Mean IOP was 1.18 mm Hg lower in the lens extraction group.

QoL was higher in CLE group, reduced cost over 10 year span

In patients with cataracts, extraction alone can significantly reduce IOP
Needs to be considered for 1st line treatment



LPI

LPI is standard of care first line treatment for ACC

After the corneal media is cleared may perform

Eliminates pupillary block and can reduce ACC in patients with Angle Closure Syndrome (ACS)

After an episode of AAC the fellow eye should be treated- up to 51% likelihood it will undergo ACC in future

Prophylaxis in occludable angles?

LPI

- ZAP Study

- All subjects had narrow angles in both eyes, so one eye was randomly assigned to receive an LPI while the other eye was the control. The endpoint for the study was primary angle closure, and/or PAS develop, or an acute angle closure attack happens. The aim was to see how often the eye that received an LPI reached that endpoint, compared to the eye that was simply observed.
- About **4%** of the eyes left untreated progressed during the five-year follow-up period; that translates to less than 1 percent per year. However, the study did find that doing the laser reduced the risk to **2.2%**.

- Singapore ANA-LIS Trial

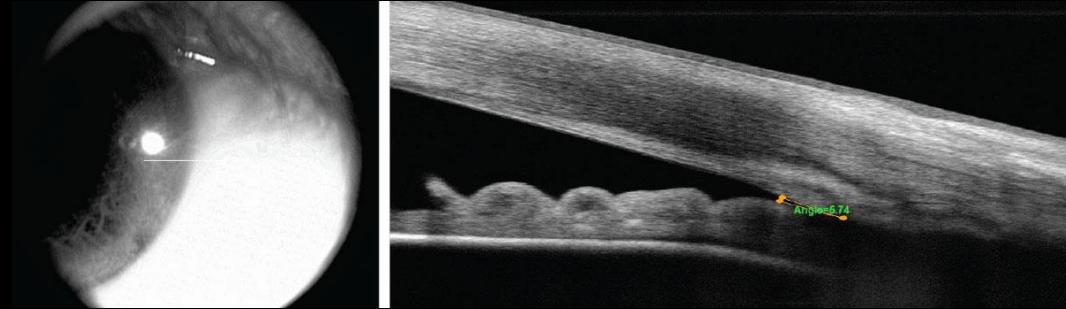
- The findings from this study were similar to the ZAP study. The primary difference was that they found higher progression rates from angle-closure suspect to primary angle closure: Almost 10 percent of our PACS subjects progressed within five years. However, the benefit of performing an LPI was the same: **Doing an LPI reduced the risk by half.**

Mingguang H, Jiang Y, Huang S, et al. Laser peripheral iridotomy for the prevention of angle closure: a single-centre, randomised controlled trial. *Lancet*. 2019;393(10181):1609-1618.

Baskaran, M., Kumar, R. S., Friedman, D. S., Lu, Q., Wong, H., Chew, P. T., Lavanya, R., Narayanaswamy, A., Perera, S. A., Foster, P. J., & Aung, T. (2022). The Singapore Asymptomatic Narrow Angles Laser Iridotomy Study. *Ophthalmology*, 129(2), 147–158. <https://doi.org/10.1016/j.ophtha.2021.08.017>

LPI- When to Consider

- Inability to visualize at least 180 degrees of angle
- Anterior segment OCT showing angles of less than 10 degrees
- Anterior segment OCT showing an anterior chamber depth that is less than 2.5mm
- Symptomatic
- Family history
- Poor ability to follow up
- Medico- legal considerations



LPI- Pearls

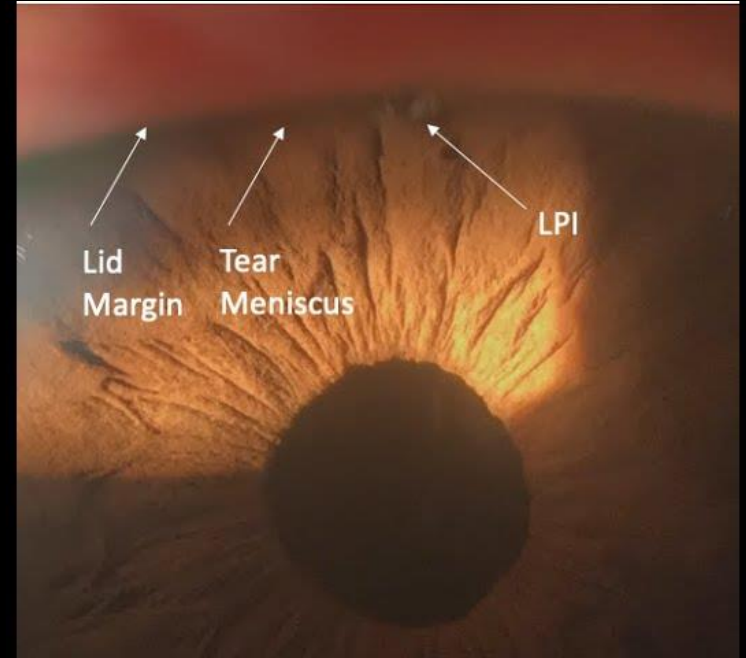
Must have clear media- reduce iop and
and eliminate corneal edema before
attempting

Coupling agent

Careful placement of opening to
eliminate side effects

10% of patients report a visual
disturbance, a line or flickering light or
movement

I place at 11/1 o'clock when there is
adequate lid coverage. If the tear
meniscus overlays any portion of opening
will have side effects. Perform nasal or
temporal in these patients



LPI Procedure

- 1064 nm YAG Laser
- 2.0-6.0 mJ, single/double burst- 3.5mJ
- Pre treatment drop of brimonidine, pilocarpine, anesthetic
- Optomap, vitals, IOP, consent
- Abraham LPI lens
- Aim for a crypt and apply until a plume of pigment is seen and then widen opening to approximately 0.3-0.5mm
- Post op medications: brimonidine; Pred Forte QID x 4 days
- Follow up in 1-2 weeks for patency
- 10 day global period



LPI



Thank You

- jmunsell25@gmail.com