

## Check It Out Before You Check It In !



Dianna Graves, BS Ed, COMT has no financial relationships to disclose. She is an Independent Continuing Education Consultant.



## What Your Doctor Wants To See Before You Dilate Them

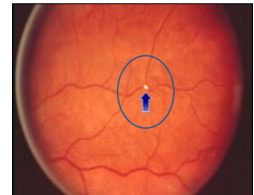1. Monocular Vision Loss
2. New Onset Diplopia
3. Narrow Angles
4. Facial Trauma
5. Pupil Differences or Ruptured Globe ?
6. Infections/Shingles



## Monocular Vision Loss

There are a large number of reasons for monocular, non-traumatic vision loss, including:

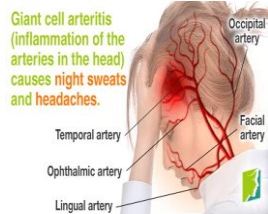
- Giant Cell Arteritis
- Vitreous Detachment
- Retinal Detachment
- Central Retinal Vein Occlusion
- Central Retinal Artery Occlusion
- Amaurosis Fugax



learnneurosurgery.com

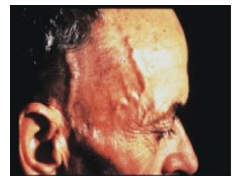## Questions to Ask The Patient

- How have you been feeling lately ? Any unplanned weight loss, malaise, neck or head pain.
- Pain or chewing and/or eating
- Headache
- Scalp tenderness - or pain along the temporal artery ?
- Floaters or Flashes
- Vision comes and goes



pinterest.com

\*\* Does it hurt to comb your hair ?



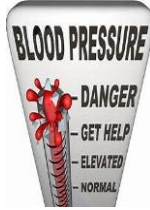IF the answer is **YES** to these "hair" and "temporal" questions.... then the doctor is going to want to see the patient to determine the course of the exam. Eventually a **SED RATE (Westergren Test)** will be ordered.

TIP: **Women:**  $\frac{\text{Age} + 10}{2}$     **MEN:**  $\frac{\text{AGE}}{2}$

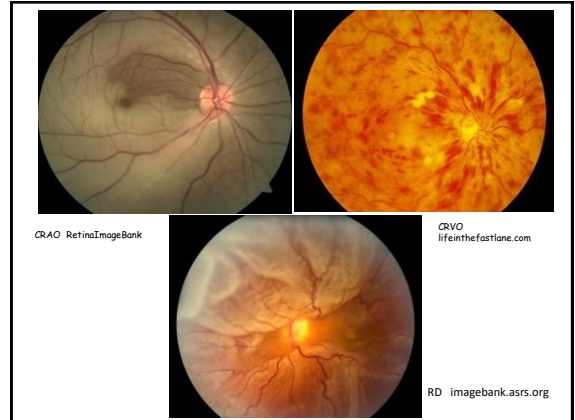
## More Questions ☺

- Do you have high blood pressure - or take blood pressure medicine
- Did your vision come and then go.. how long did it "go"
- Do you see a curtain or do you see flashing lights

With these questions, we are trying to discern if there has been a retina/vitreous issue, or to see if they have had a CRAO or CRVO.



optimalwellnesslabs.com

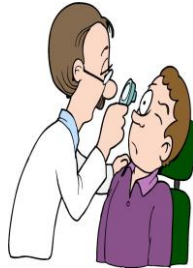

CRAO RetinaImageBank

CRVO lifeinthefastlane.com

RD imagebank.asrs.org

The doctor is going to want to do a dilated fundus exam to make sure there are no vessel occlusions causing that might be leading to the loss of vision. They will look for plaque particles that might have been "thrown" from the heart or carotid blood vessels (Amaurosis Fugax).



## New Onset Diplopia

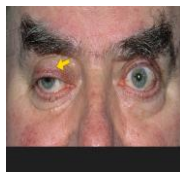
Diplopia is most commonly a symptom of eye misalignment. It may occur due to something as simple as a change in refractive error. But, on the other end of the spectrum, diplopia is usually the first sign of a muscular or neurological disorder.

- Stroke or transient ischemic attack (TIA)
- Aneurysm
- Diabetes
- Myasthenia gravis
- Brain tumor/cancer
- Multiple sclerosis
- Trauma



## Diabetic III Nerve Palsy :

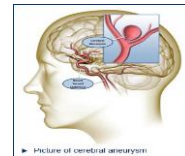
A complete third nerve palsy causes a totally closed eyelid and the eye is pointing outward and downward. The eye cannot move in or up, and the pupil is typically enlarged and does not react normally to light. Diplopia usually occurs because the eye is misaligned.



reference.medscape.com

## Brain Aneurysm

- Localized Headache
- Dilated pupils
- Blurred or double vision
- Pain above and behind eye
- Weakness and numbness
- Difficulty speaking



Ruptured brain aneurysms usually result in a subarachnoid hemorrhage (SAH), which is defined as bleeding into the subarachnoid space. When blood escapes into the space around the brain, it can cause sudden symptoms.

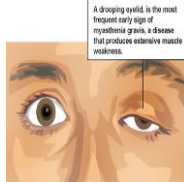
www.bafund.org

## Myasthenia Gravis

Myasthenia gravis is an **autoimmune disease** that commonly occurs in women under the age of 40 and in men over the age of 60. It is uncommon in children. Muscle weakness becomes progressively worse during physical activity and improves after resting. Weakness and fatigue are worse toward the end of the day.

### Symptoms:

- Muscle fatigue, to the point of immobility
- Double vision
- Ptosis (a drooping eyelid)
- Difficulty holding up the head
- Fatigue
- Vocal changes
- Weakness of the facial muscles, affecting speech and chewing or swallowing



Wikipedia.com nation.lk

## Questions To Ask

- Is diplopia side by side or one higher than the other ?

- Is the diplopia monocular or binocular?

This is the **first** question you should ask. Have the patient check to see if the double vision goes away if they close one eye. Binocular diplopia goes away when either eye is closed and is caused by misalignment of the eyes. Monocular diplopia (rare) goes away with only one particular eye closed.



- Does the diplopia progress or remain stable? Certain diagnoses are more likely to be progressive (get worse as the day goes on), such as multiple sclerosis, myasthenia gravis, and thyroid disease. Others occur suddenly and remain stable, such as cranial nerve palsy



- Is it worse distance or near ?

This question is designed to rule out a divergence excess or convergence insufficiency.

- Any headache or nausea/vomiting ?
- What systemic medical issues do they have ?

## Narrow Angles

Some patients have shallow anterior chambers. This can cause a narrowing of "the angle". When this happens, the iris can be pushed into the angle (and trabecular meshwork) when the pupil is dilated (either with drops or by dim lighting).

This will cause a closing off of the angle, aqueous not being allowed to leave the AC, and an increase in IOP.



## How Does This Happen ?!

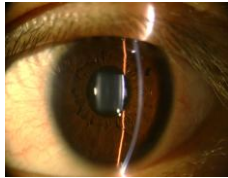
Think of the iris as an accordion door. When you dilate the pupil....the door will be "pushed" into the "angle" and shut off aqueous from flowing into the trabecular meshwork. This causes the IOP to rise quickly.



### What We Are Trying to Evaluate Is If The Patient Has "Narrow Angles"

Eye pressure can rise very high in a short period of time. When this happens - the patient can report the following symptoms:

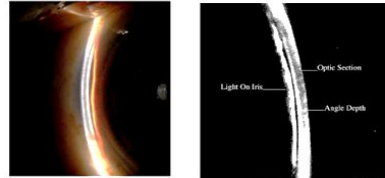
- Blurry vision
- Red eyes
- Headache
- Eye pain
- Halos around lights
- Mid-dilated pupil
- **Nausea**



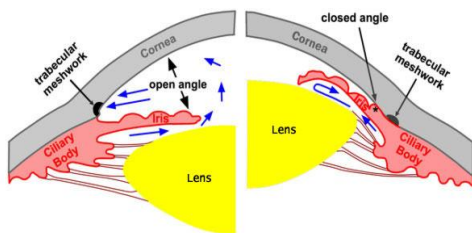
enictivudilla.com

What We Really Are Looking At Is The Anterior Chamber Depth - The Doctor Is The One To Evaluate The Angle by GONIO EXAM !

Tech "Angles" = AC depth

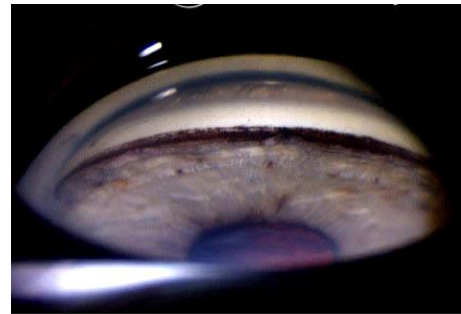


### Open vrs Narrow Angle



lookfordiagnosis.com

### The "Real" Angle !

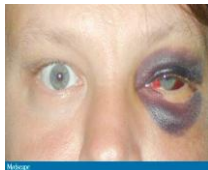

dro.hs.columbia.edu

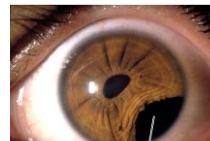### Facial Trauma

Patient arrives to your office with a "black eye".

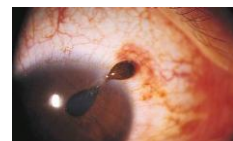
States their vision is fuzzy, they have cheek numbness and the whole area around the eye feels "tight". They are also complaining of nausea (and actually threw up before they came to clinic) and a headache. Your clinic has a policy to dilate all black eyes. What "things" do you potentially need to be aware of before you do so ?



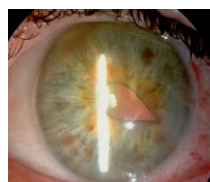medscape.com



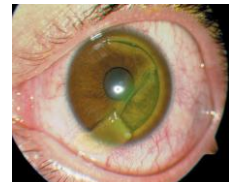bingispis.com



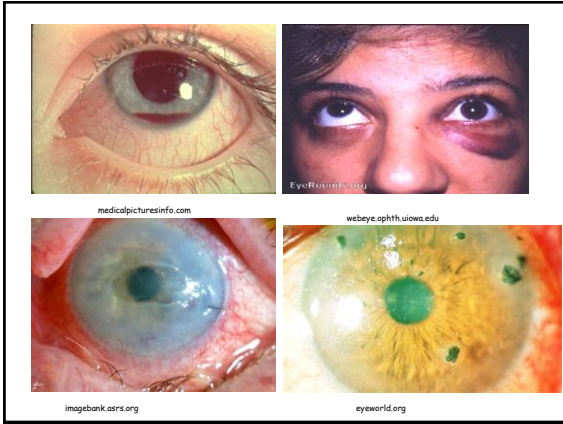oneskey.com



jerseyjournal.org

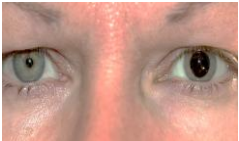


documentingreality.com




## Anisocoria

**Unequal pupil size .**  
Affects approx. 20% of the population. It can be harmless or can be a symptom of a more serious medical problem. It is generally defined as the difference of 0.4 mm between the two pupils or more. It is important to establish whether the anisocoria is more obvious in dim or bright light to determine whether the larger pupil or smaller pupil is the abnormal one.

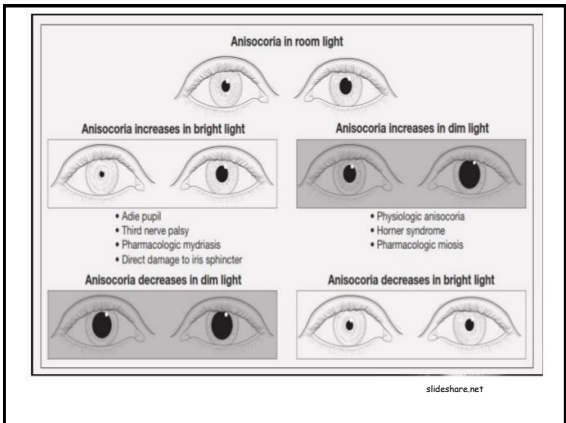



Aspos.org  
theketelsens.blogspot.it



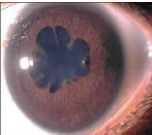
- Anisocoria that is worse in the dark suggests the smaller pupil (which should dilate in the dark) is the abnormal pupil and suggests **Horner's syndrome**. In Horner's syndrome, the sympathetic nerve fibers have a defect, causing the pupil of the involved eye to not dilate in darkness. **If the smaller pupil dilates in response to Apraclonidine** (Iopidine) drops, this suggests Horner's syndrome is present.
- Anisocoria that is greater in bright light suggests the larger pupil (which should constrict in bright conditions) is the abnormal pupil. This may suggest **Adie tonic pupil**, "drug" dilation (drops, "took something"), oculomotor nerve palsy, or a damaged iris.

keywordssuggest.org

**Physiological anisocoria:** A difference in pupil size for no medical reason. In this condition, the difference between pupils is usually less than 1 mm.

**Mechanical anisocoria:** Past eye trauma, surgery, or inflammation (uveitis, angle closure glaucoma) can cause adhesions (synechiae) between the iris and the lens




cmj.org.za

**Horner's Syndrome:**

- \* ptosis
- \* miosis
- \* anhidrosis

It is defined as an interruption of the sympathetic nerve supply to the eye

**Localization of the Lesion**



keywordhut.com      merckmanuals.com

## APD (Marcus Gunn)

A relative afferent pupillary defect (RAPD) does not cause anisocoria. Often seen in optic neuritis (MS).

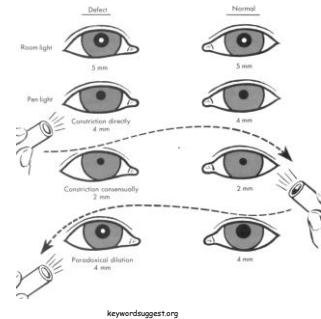
Potential causes:

1. optic neuritis
2. optic nerve tumor (rare)
3. optic nerve inflammation
4. severe glaucoma (because of optic nerve involvement)



## Swinging Flashlight Test

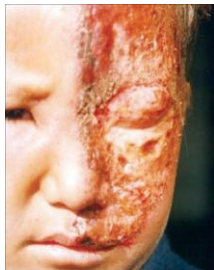When the pupil only *slightly* contracts, or even dilates when light is shined over it, instead of shrinking immediately like it should.



## Shingles : When Are They Contagious ?

Chickenpox Virus (varicella).

The rash follows "respects the midline," meaning that it occurs on only one side of the forehead, one side of the nose, and on the upper, but *not usually lower, eyelid*. The upper lid may sometimes have swelling similar to that of cellulitis



e-ijid.org

## What "Causes" Shingles?

The virus is the **varicella zoster virus** which is the same virus that causes chickenpox and shingles. After it has infected the person (usually a young child), the virus remains in the body in a dormant state. Then it will re-occur in the form of shingles when people begin to age, go through any physical or emotional stress or prolonged illness, and/or when they are in immunocompromised states.



## Symptoms

- eye redness
- aching or pain in/around the eye
- photophobia (because of cornea involvement)
- watering of the eye
- blurry vision
- blisters/ rash around the eyelids



## Are Shingles Contagious?

Shingles (varicella zoster virus (VZV), is not contagious. "Shingles" should not be confused with herpes simplex virus (HSV 1 or 2) infections (which are sexually transmitted form of herpes).

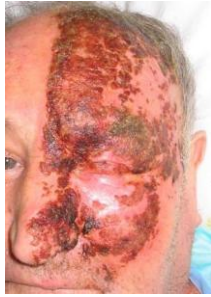The zoster virus is infectious when the blisters are weeping and oozing. When they blisters have scabbed over, they are usually not considered infectious. A recurrent outbreak of shingles is not a new infection, but actually a reactivation of the dormant virus.



## Hutchinson's Sign

Lesions on the side or tip of the nose is a strong indicator of ocular involvement.

The blisters strictly obey the midline with involvement of one or more branches of the ophthalmic division of the Trigeminal Nerve (CN V - facial nerve).

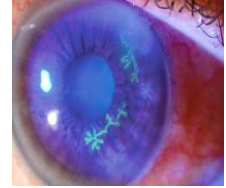

Studyblue.com

## Corneal Dendrites

The ulcer is not round with a smooth edges with little end bulbs, which stain very brightly with **Fluorescein** due to missing epithelial cells.

The underlying cornea has minimal inflammation.



Medlinks.blogspot.com



diannagraves1017@gmail.com