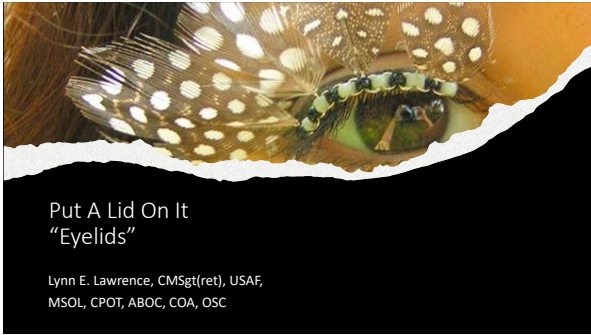



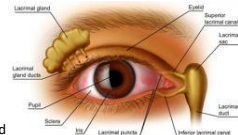
Put A Lid On It "Eyelids"

Lynn E. Lawrence, CMSgt(ret), USAF, MSOL, CPOT, ABOC, COA, OSC

1

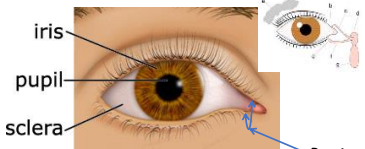
Objectives

- Lid anatomy
- Malfunctions of the eyelid
- Diseases of the eyelid
- Impact upon vision
 - Spectacles
 - Contact lenses
- Surgeries associated with the eyelid



2

Anatomy

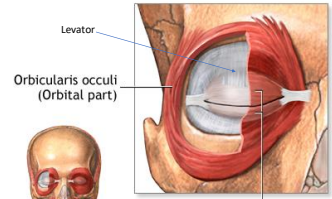


What function does the punctum have?

3

Eyelid Anatomy

Understanding eyelid anatomy aids in understanding the condition and educating the patients



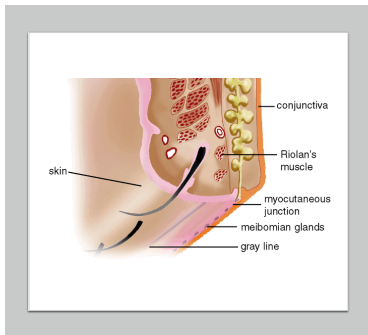
Orbicularis oculi (Palpebral part)

ADAM

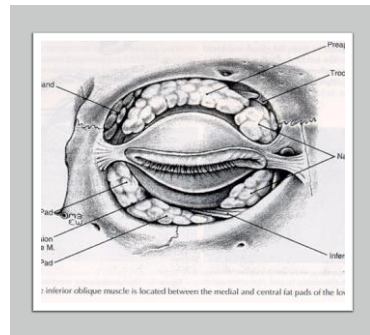
4

Anatomy Cont....

- Muscle function
- Nerve innervation
- Lid Position
 - Asymmetry
 - Brow appearance



5



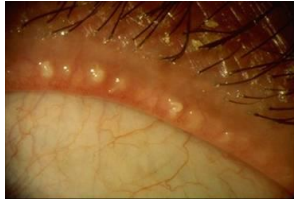
6

Internal and External

- Observe the patient
 - Head position
 - Lid position
 - Inversion
 - Defect
- Identify defect through exam
 - MRD1
 - MRD2
- Signs and symptoms documented

Clogged Meibomian Glands

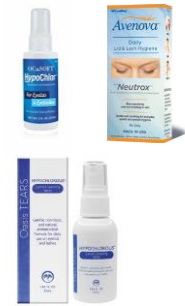- MDG = meibomian gland dysfunction
- Major contributor to Ocular Surface Disease
- Should be inspected at every comprehensive exam and when case Hx dictates
- Debriding unclogs



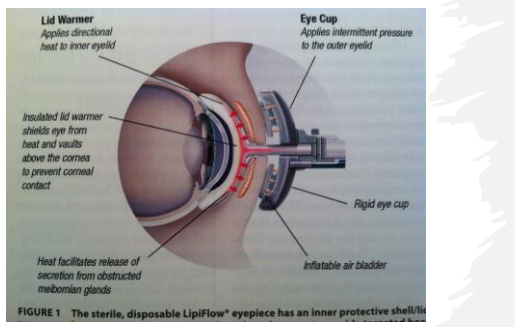
13

New Treatments

- Ocular Lid Scrubs
- HypoChlor is OTC
- Avenova with neutrox Rx
 - Hypochlorous acid has a bacteria killing capacity
 - Everyday lid care
 - Removes germs and bacteria
 - Stable for 3 years in glass bottle
 - Medvantx Mail Order
 - \$35 or \$60



14



15

Blepharospasm

(eyelid twitching) is an involuntary spasm of the eyelid muscle. The most common factors that make the muscle in the eyelid twitch are fatigue, stress, and caffeine.¹² Eyelid twitching is not considered a harmful condition and therefore there is no treatment available. Patients are however advised to get more sleep and drink less caffeine.

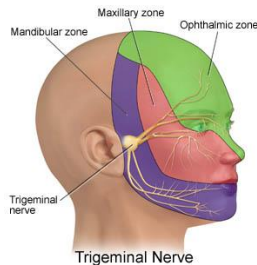
*Ice has been known to help with reducing the effects of the twitching



16

5th Cranial Nerve - Trigeminal

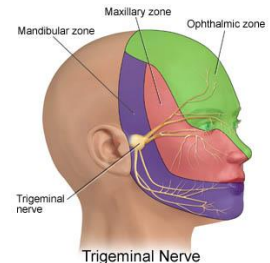
- Corneal sensitivity
- Lacrimal gland innervation
- The trigeminal nerve is a nerve responsible for sensation in the face and motor functions such as biting and chewing. The largest of the cranial nerves, its name derives from the fact that each trigeminal nerve has three major branches: the ophthalmic nerve, the maxillary nerve, and the mandibular nerve. The ophthalmic and maxillary nerves are purely sensory, and the mandibular nerve has sensory and motor functions



17

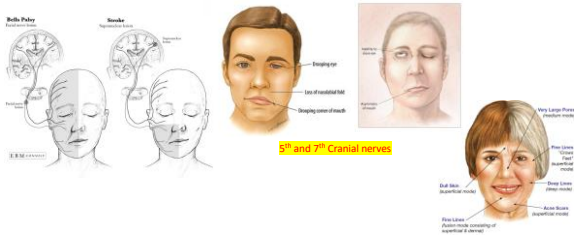
Facial Nerve 7th Cranial Nerve

The facial nerve is the seventh cranial nerve, or simply cranial nerve VII. It emerges from the brainstem between the pons and the medulla, controls the muscles of facial expression, and functions in the conveyance of taste sensations from the anterior two-thirds of the tongue and oral cavity

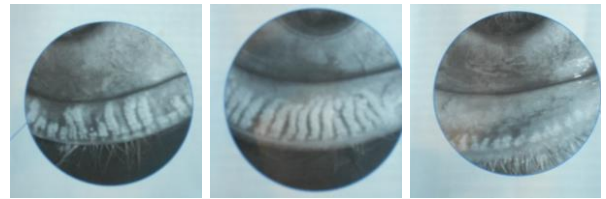


18

Aging - Bell's Palsy - Stroke



19

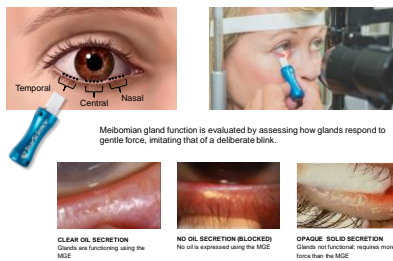


Ocular Surface Disease

- We no longer call OSD "dry eyes"
- This disease is impacting millions
- Targets women more than men

20

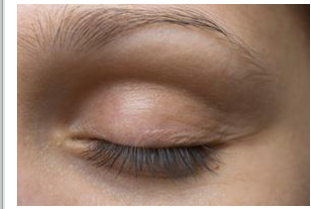Meibomian Gland Evaluator



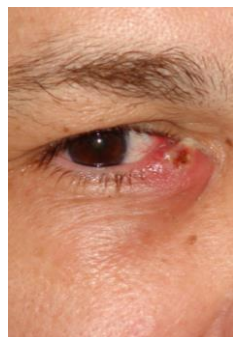
21

Blinking: Lid Seal

- When you get a proper seal upon a blink, the following occurs:
 - Old flora is removed from the ocular surface
 - Oil is expressed from the meibomian glands when the eyes are forced together
 - Fresh tears are drawn onto the ocular surface



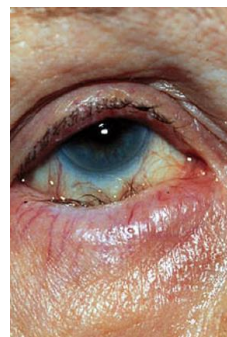
22



Nasal Lacrimal Duct Obstruction

- Punctum: 1 upper and 1 lower
- Lid position
- Trauma / Disease
- Lacrimal irrigation
- Nose surgery

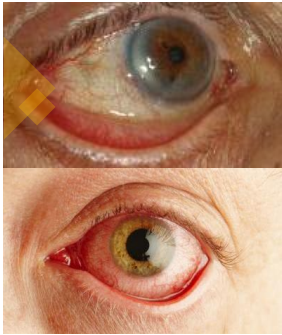
23



Entropion

Entropion (en-TROH-pee-on) is a condition in which your eyelid turns inward so that your eyelashes and skin rub against the eye surface. This causes irritation and discomfort.

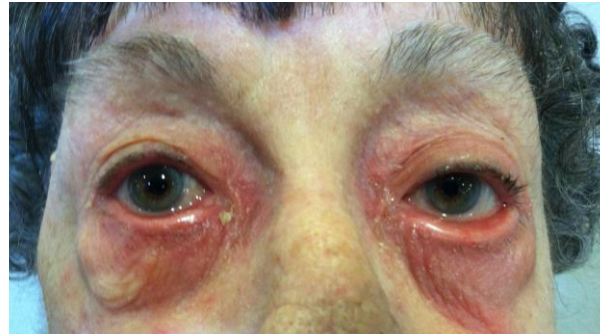24



Ectropion

- Ectropion (ek-TROH-pee-on) is a condition in which **your eyelid turns outward**. This leaves the inner eyelid surface exposed and prone to irritation.
- Ectropion is more common in older adults, and it generally affects only the lower eyelid. In severe ectropion, the entire length of the eyelid is turned out. In less severe ectropion, only one segment of the eyelid sags away from the eye.

25



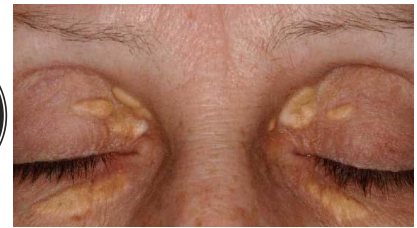26

Eyelid Tattoo's

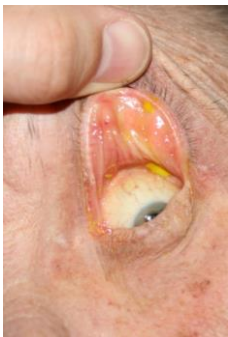

- Growing trends
- Eyebrow tattooing most common form
- Permanent make-up

27



28



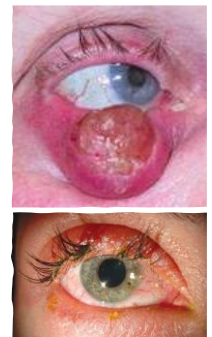Floppy Eye Lid Syndrome

- Lid laxity on upper or lower lids
- More common (COPD/Sleep Apnea)
- Dx often missed
- Reoccurring eye infections
- Neck size 16in (40.64cm) or larger

29

Cancer of the lids

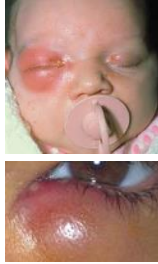- Look for unexplained missing eyelashes upon slit lamp exam
- Early detection and intervention produces most successful outcomes
- Follow-up important



30

Dacryocystitis

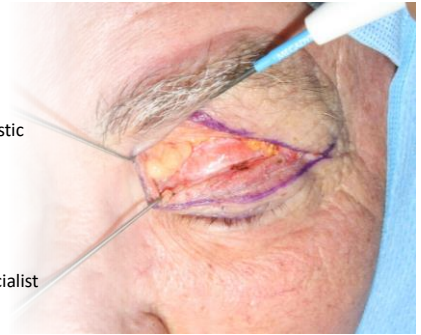
Dacryocystitis is an infection of the lacrimal sac, secondary to obstruction of the nasolacrimal duct at the junction of lacrimal sac. The term derives from the Greek dakryon, cysta, and -itis. It causes pain, redness, and swelling over the inner aspect of the lower eyelid and epiphora. When nasolacrimal duct obstruction is secondary to a congenital barrier it is referred to as dacryocystocele. It is most commonly caused by Staphylococcus aureus and Streptococcus pneumoniae.



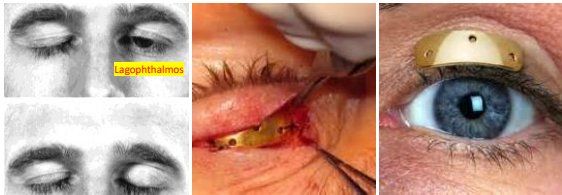31

Surgery

- Ocular facial plastic surgeon
- Mistakes can be permanent
- Seek ocular specialist



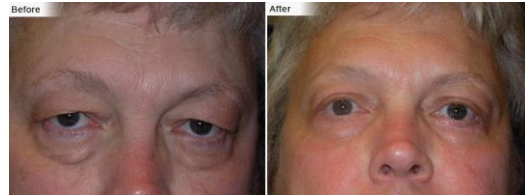32



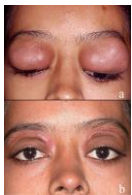Gold Weights

33

Dermatochalasis

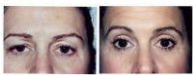

34



Causes of Droopy Lids

- Over 425 causes of droopy eyelids
- Aging
- Muscular
- Neurological
- Congenital
- Acquired
 - Disease
 - Trauma

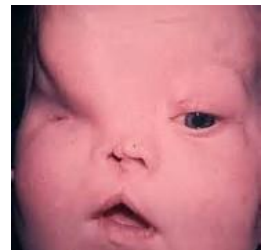

35

Birth defects

Ablepharia

Ablepharia (ablepharon) Congenital absence of or reduction in the size of the eyelids



36

Marcus Gunn

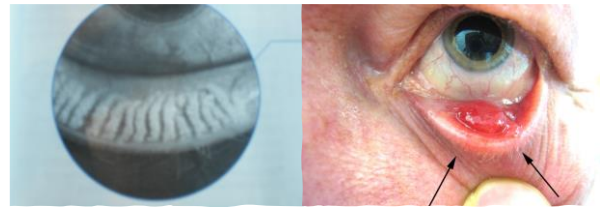
Marcus Gunn phenomenon (a.k.a. Marcus Gunn Jaw-Winking^{1,2} or Trigemino-oculomotor Synkineses) is an **autosomal-dominant** condition with **incomplete penetrance**, in which nursing infants will have rhythmic upward jerking of their upper eyelid. This condition is characterized as a **synkinesis**: when two or more muscles that are independently innervated have either simultaneous or coordinated movements

Rachel Schoffner, ESG, Memphis, TN



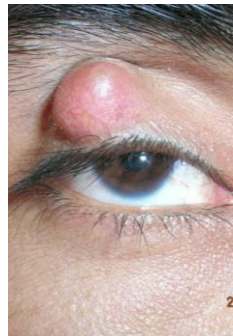Yamada K, Hunter DG, Andrews C, Engle EC (September 2005). "A novel MYO2A mutation in a patient with congenital blepharic of the extraocular muscles and Marcus Gunn jaw-winking phenomenon"

37



Chalazions

38



Cyst and Tumors

- Ocular Facial Plastic Surgeon
- Some are cancerous
- Refer immediately for suspicious growth

39



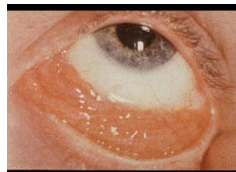
Warm Compresses

- Treatment for Chalazions should be explained
- Repetitive treatments of hot water to the face can complicate the disease
- Wash clothes maintain bacteria, use caution
- There are masks available for heat therapy

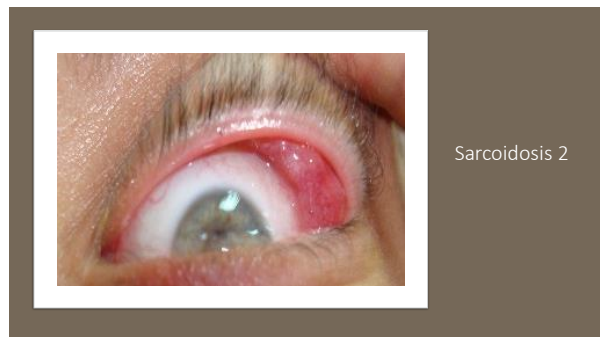
40

Sarcoidosis

- Sarcoidosis is the growth of tiny collections of inflammatory cells (granulomas) in different parts of your body — most commonly the lungs, lymph nodes, eyes and skin.
- Doctors believe sarcoidosis results from the body's immune system responding to an unknown substance, most likely something inhaled from the air.



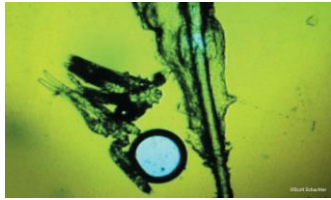
41



Sarcoidosis 2

42

DEMODOX

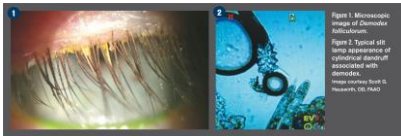


43

Demodex = Parasitic Infection

- Can be found in adults and children
- Translucent sleeve around cilia
- Demodex can be found on the base of the eye lash and can be seen by using a microscope
- They live on the lash approximately for 4-6 weeks, so treatment has to last for 8 weeks to destroy the mites and their eggs. Eliminate the food source and mites die.
- Bolo for patients with Rosacea
- Mites are more active a night, medicate BID

44



Demodex mites are microscopic ectoparasites found in human skin. They are extremely common, and their rate of infestation increases with age. The life span of demodex outside the living body is very limited. Direct contact is thought to be required for transmission of the mites. The lifecycle of demodex from egg/molt to an adult is quite short and no longer than two to three weeks. The adult stage is less than a week, and this is when mating occurs.

http://optometrytimes.modernmedicine.com/optometrytimes/news/what-s-all-craze-about-demodex?utm_campaign=Sponsored-Resource-Center&utm_source=HLS_email&utm_medium=email&utm_content=2797580_4L_2e9ee2c2Nggz-8RAGC6ARW9v9k6w4kPQ5WV_Gf4P717vnuZvng71667e9p3-20_X9F4Lx8ABRzjYf-VaXg9WKRXXGc_8q4mUw8_hsm=27975804

45

Demodex

Demodex can be found on the base of the eye lash and can be seen by using a microscope

They live on the lash approximately for 4-6 weeks, so treatment has to last for 8 weeks to destroy the mites and their eggs. Eliminate the food source and mites die.

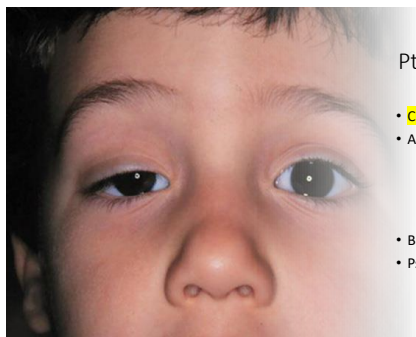
Bolo for patient's with Rosacea

Children have Demodex too

Mites are more active a night, medicate BID

<http://www.reviewofophthalmology.com/content/c/36411#.dpuj>

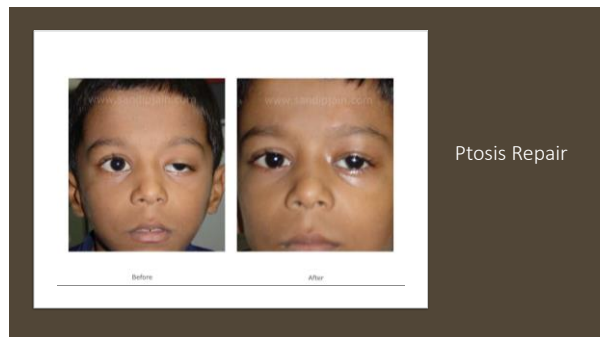46



Ptosis

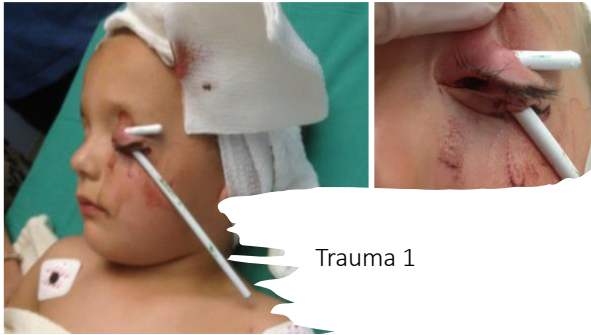- **Congenital**
- Acquired
 - Traumatic
 - Dermatochalasis
 - Muscle involvement
 - Nerve innervation
- Blepharoptosis
- Pseudo (dermatochalasis)

47



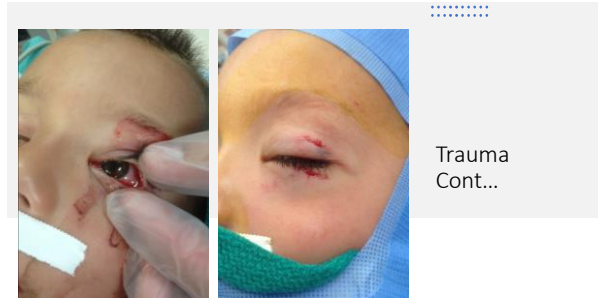
Ptosis Repair

48



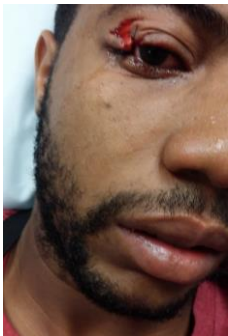
Trauma 1

49



Trauma
Cont...

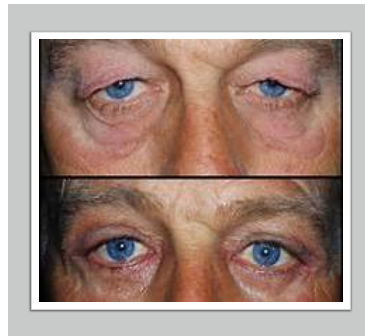
50



Trauma 2 Door Hook

- Ocular Facial Surgeon
- Emergency room repairs
- Children

51



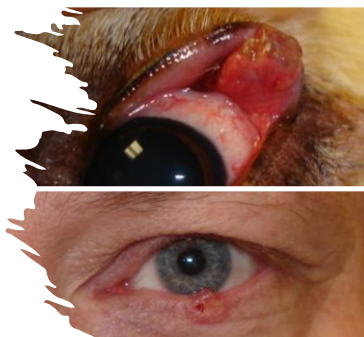Dermatochalasis Surgery

- Very common
- Drooping eyelids due to excess skin
- Not cosmetic
- Insurance covers

52

Eyelid Tumor

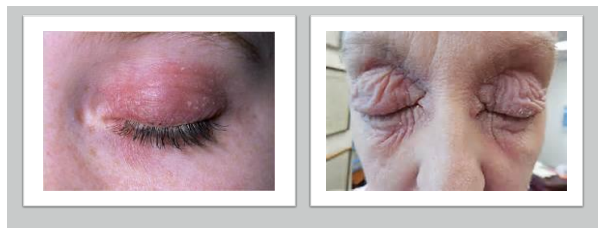
- Can be serious, even deadly
- Testing is highly recommended
- Mohs dermatologist will likely be included in the process



53

Eczema

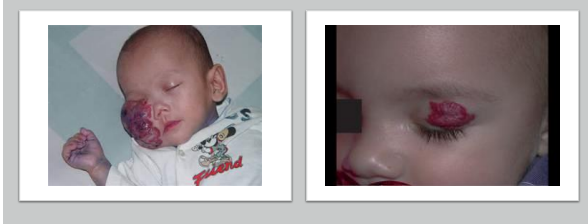
Eyelid eczema: Eyelid eczema is a chronic skin condition affecting the eyelids. The skin of the eyelids becomes itchy, red and scaly. Often other parts of the body also have eczema



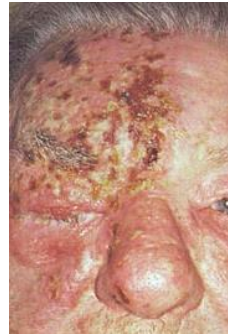54

Hemangioma

A hemangioma is a benign and usually self-involuting tumor of the endothelial cells that line blood vessels that is characterized by increased number of normal or abnormal vessels filled with blood. It usually appears in the first weeks of life and grows most rapidly over the first six months.



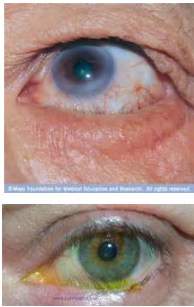55



56

Disease (Shingles)

Shingles, also known as zoster, herpes zoster, or zona, is a viral disease characterized by a painful skin rash with blisters involving a limited area. Typically, the rash occurs on either the left or right of the body or face in a single stripe. Two to four days before the rash occurs there may be pain or tingling in the area.



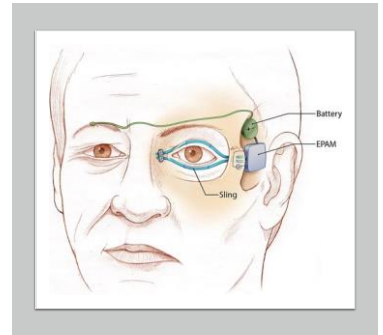
Trichiasis

Trichiasis is a medical term for abnormally positioned eyelashes that grow back toward the eye, touching the cornea or conjunctiva. This can be caused by infection, inflammation, autoimmune conditions, congenital defects, eyelid agenesis and trauma such as burns or eyelid injury

57

New advancing implant

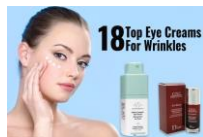Technology is always being developed and we must consider new advances as potential options for our patients




58

Temporary Cosmetic Applications

- Drink water (good all the time)
- Exercise
- Olive oil, cucumber, grapes
- Chamomile
- Botox
- Fat or fillers
- Creams provide temporary relief



59



Thank you
martralyn@msn.com

60